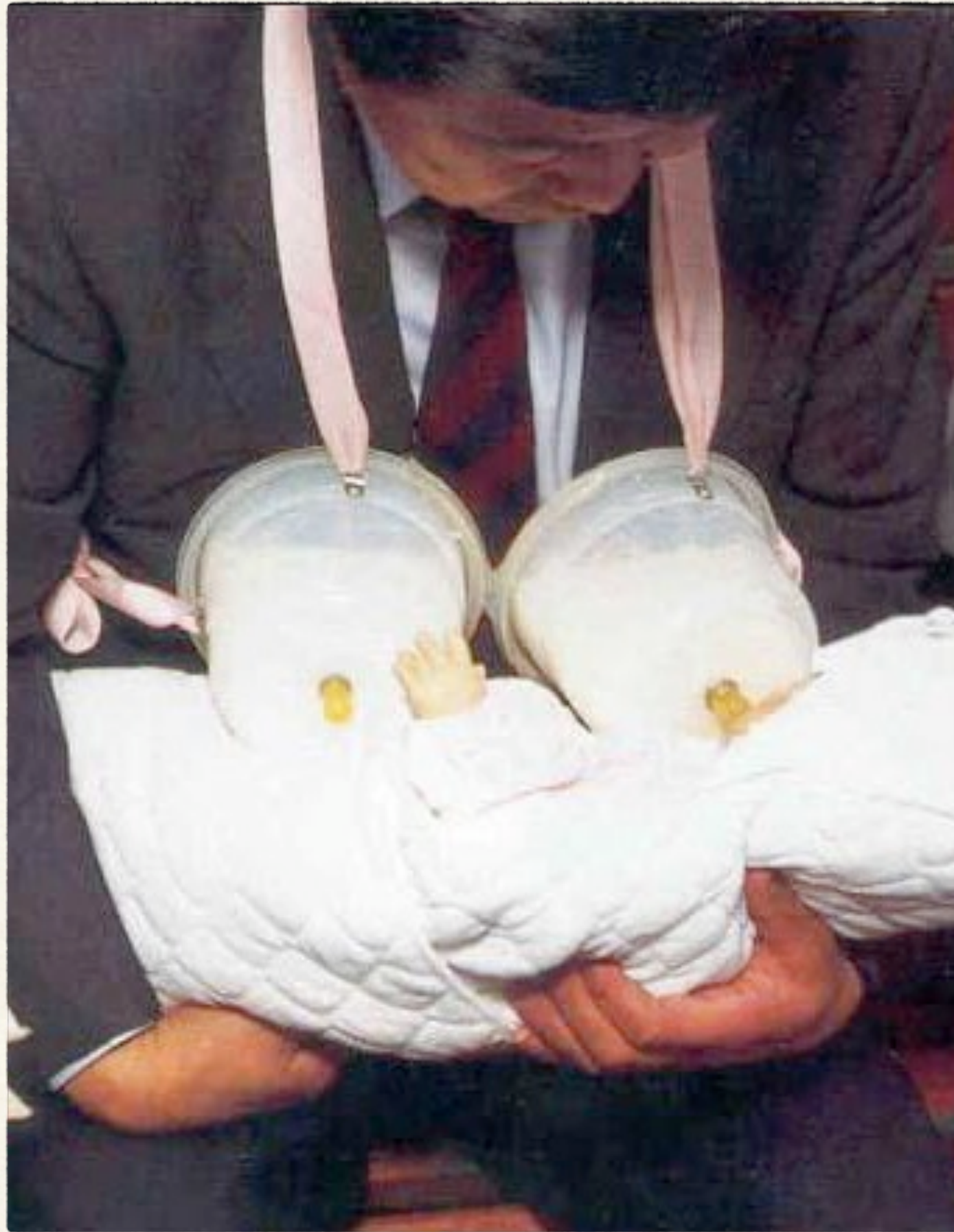


MEMELER

Dr. Seluk Tunalı
TOBB ETÜ, 26 Eylül 2014

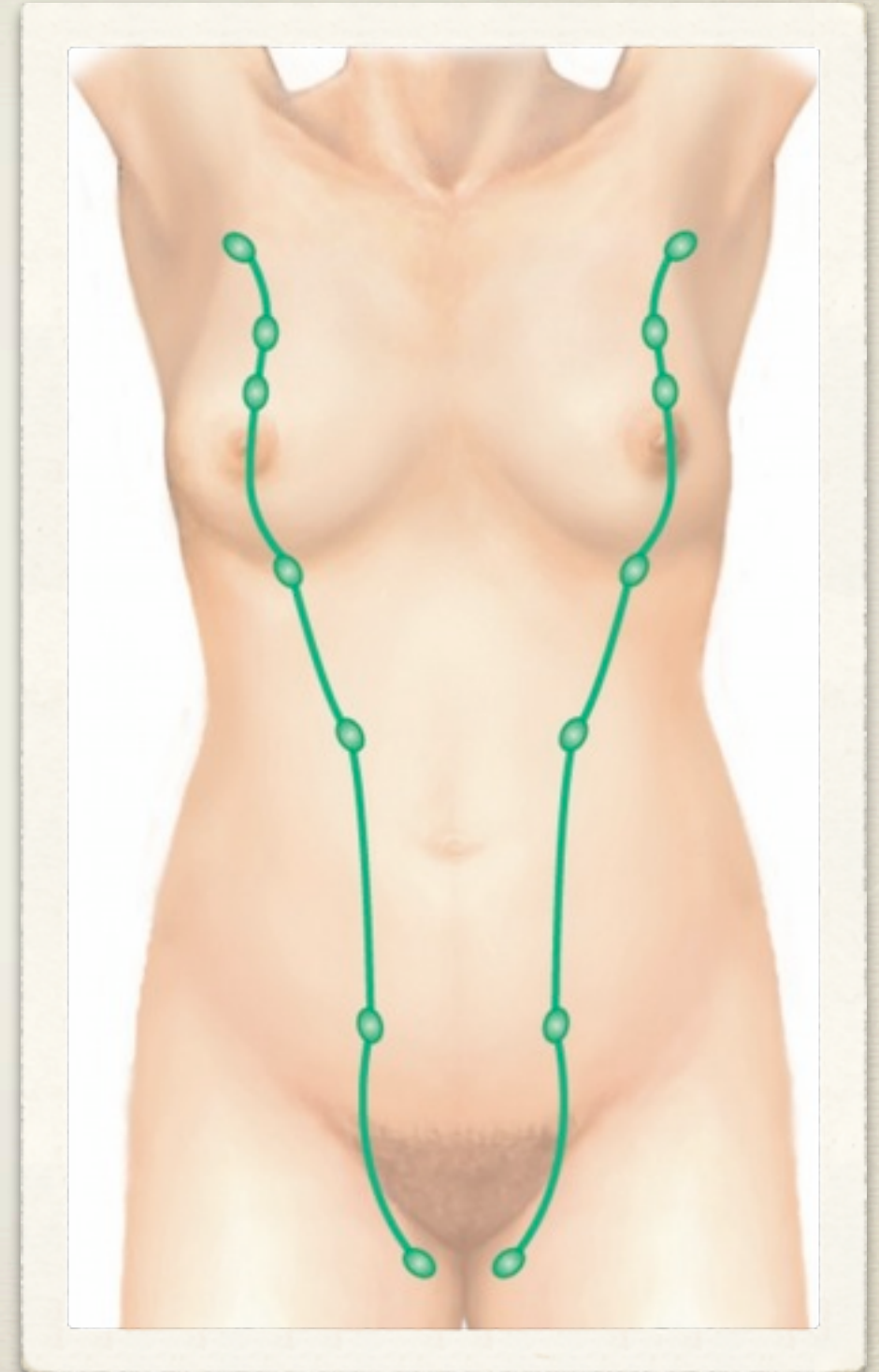


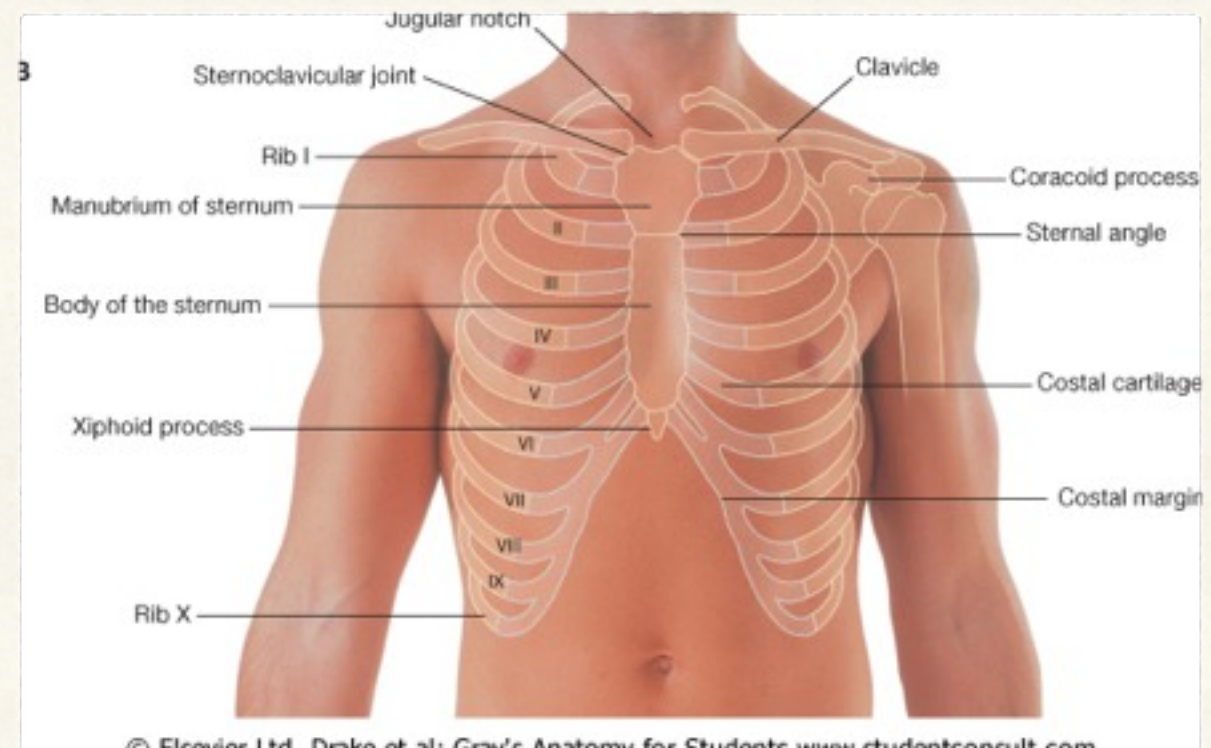
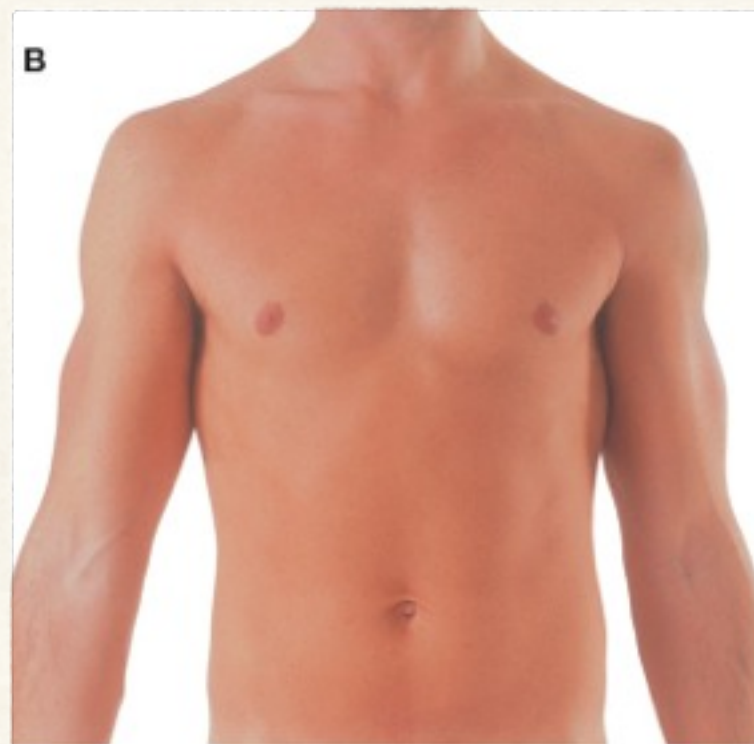
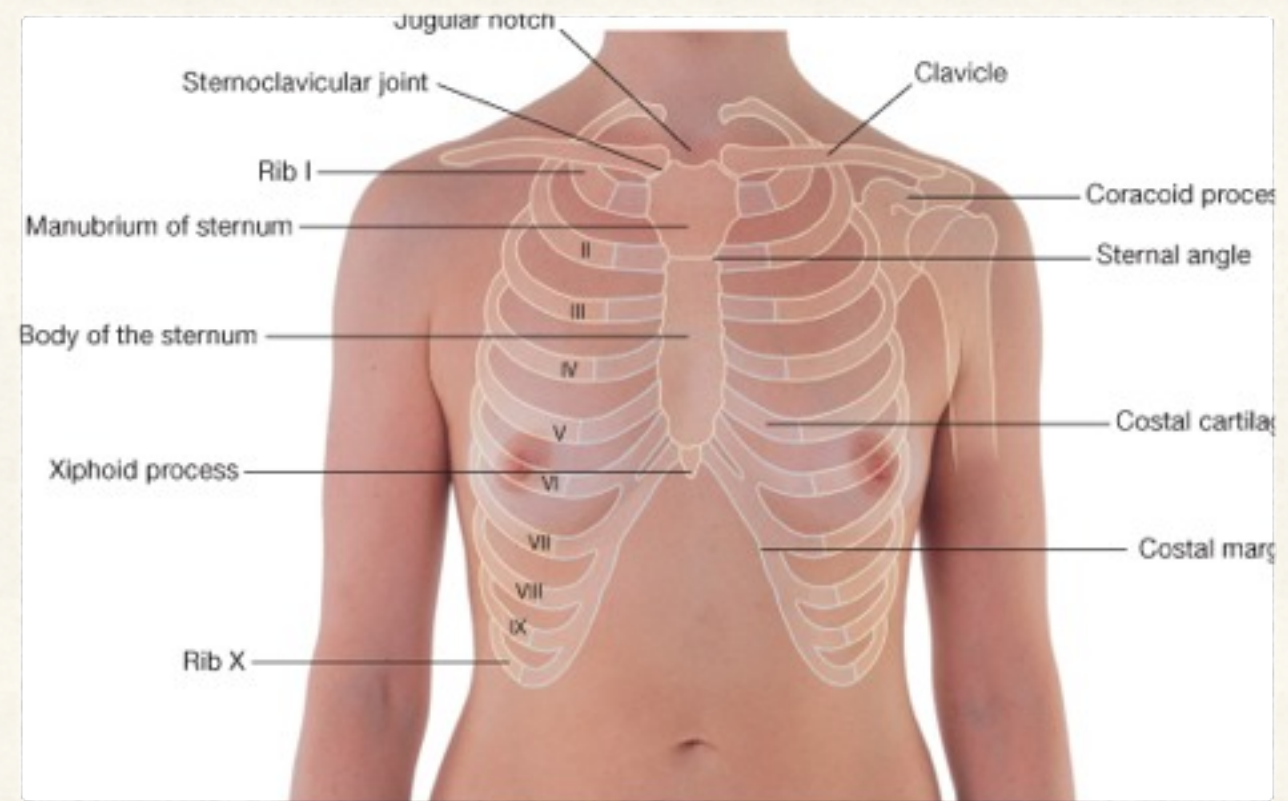
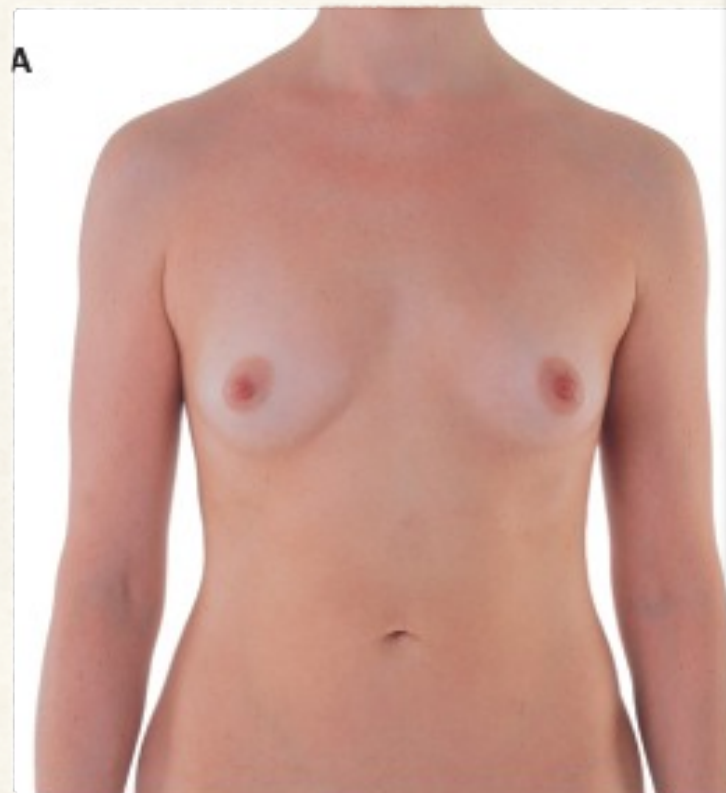



Meme Anatomisi – 1

- * Glandula mammaria
- * Stroma
- * Deri
- * Ektoderm kökenli
- * 2.-6. kostalar arasında
- * Sternum – linea axillaris mediana

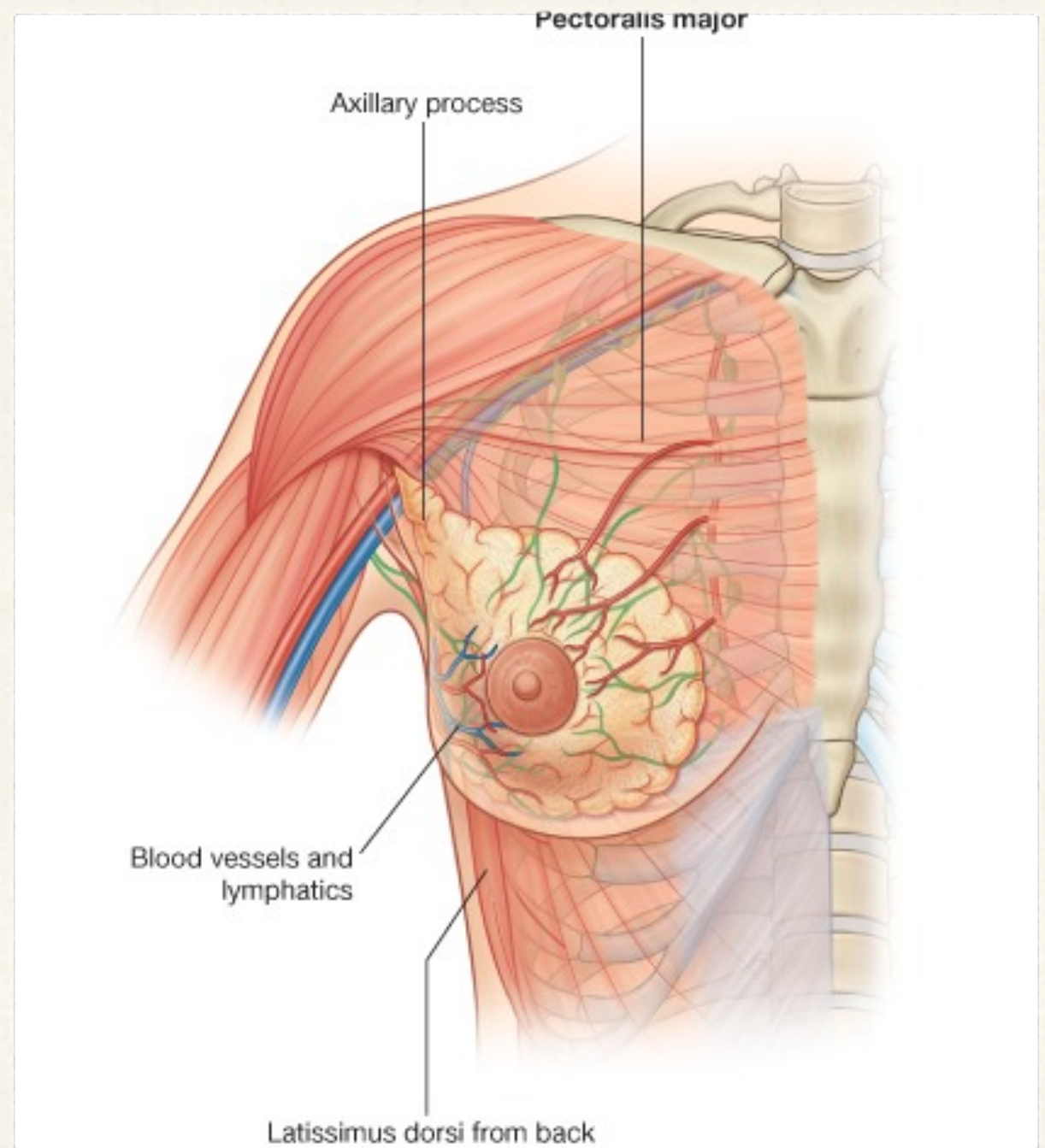


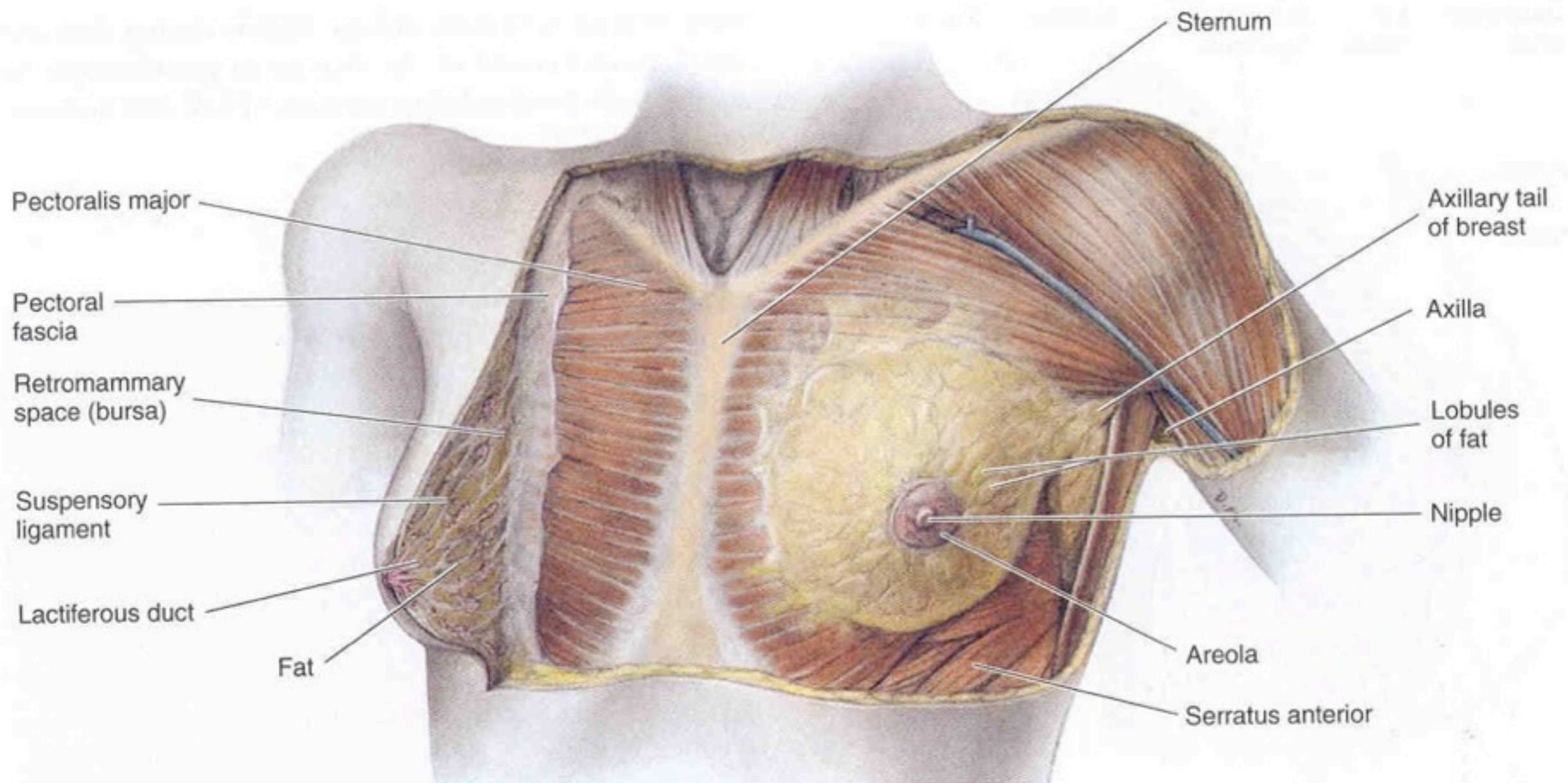


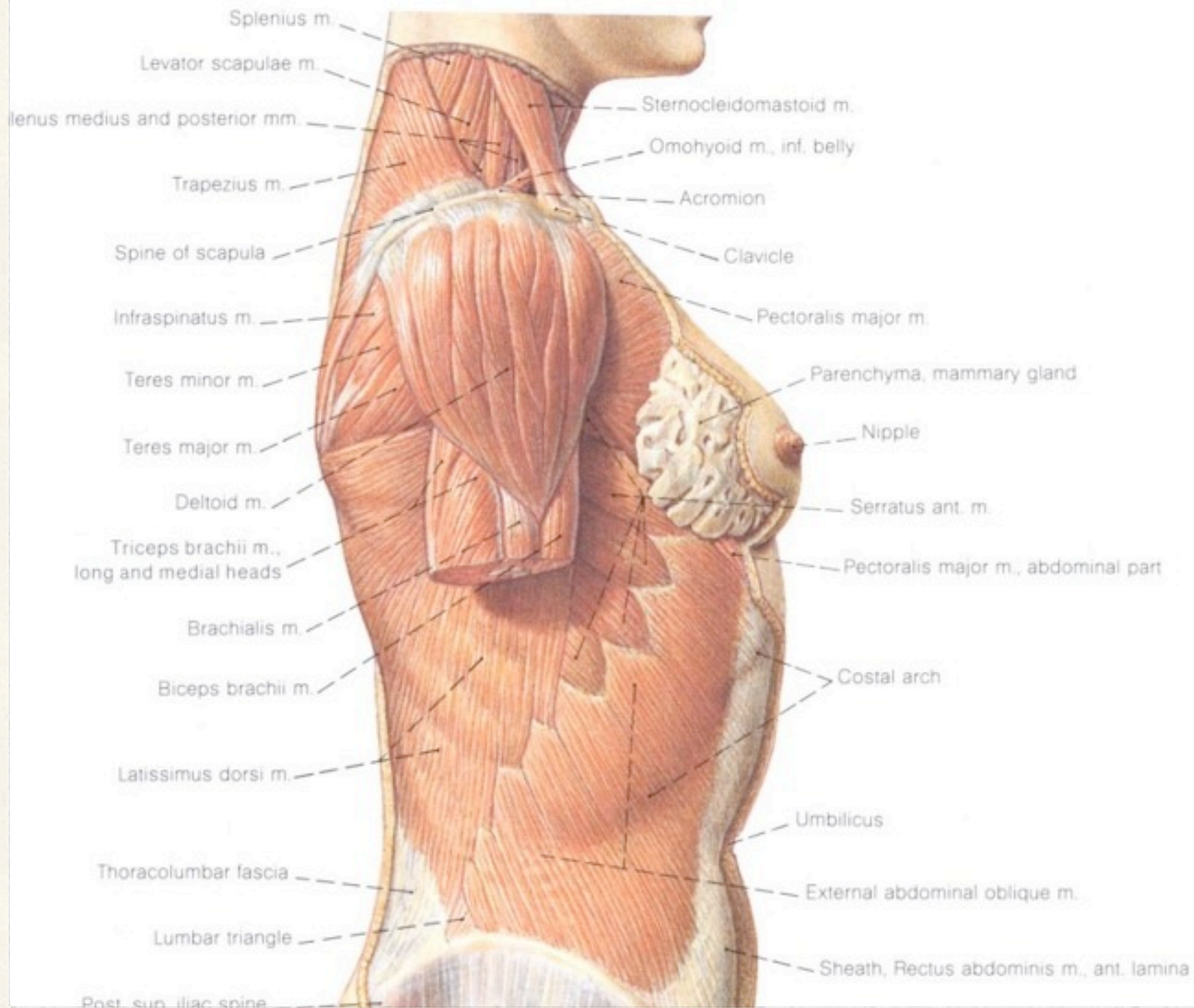
© Elsevier Ltd. Drake et al: Gray's Anatomy for Students www.studentconsult.com

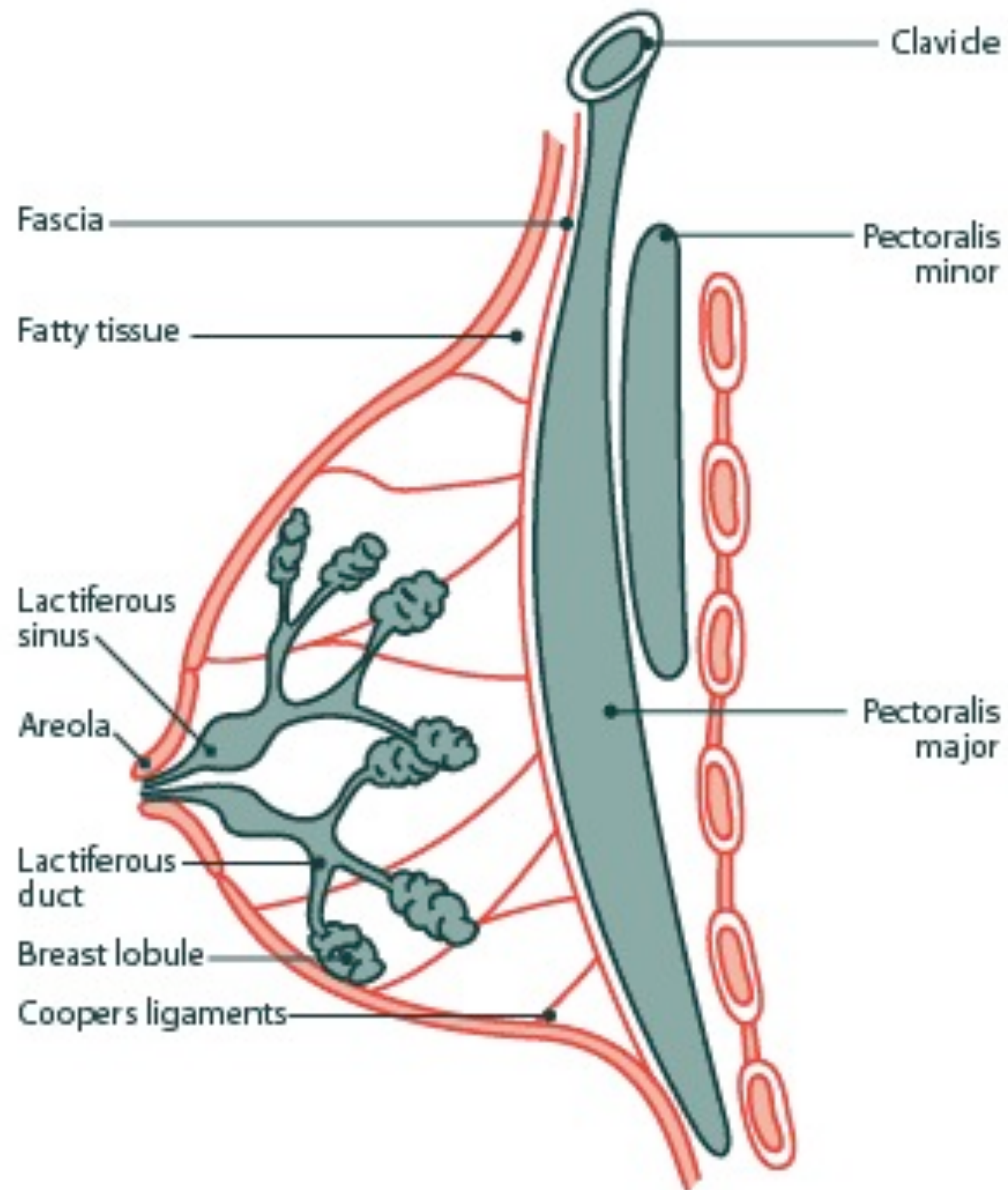
Meme Anatomisi – 2

- * Pektoral bölgenin yüzeysel fascia'sı içinde
- * Tabanında derin pektoral fascia
- * m. pectoralis major
- * m. serratus anterior
- * m. obliquus externus abdominis



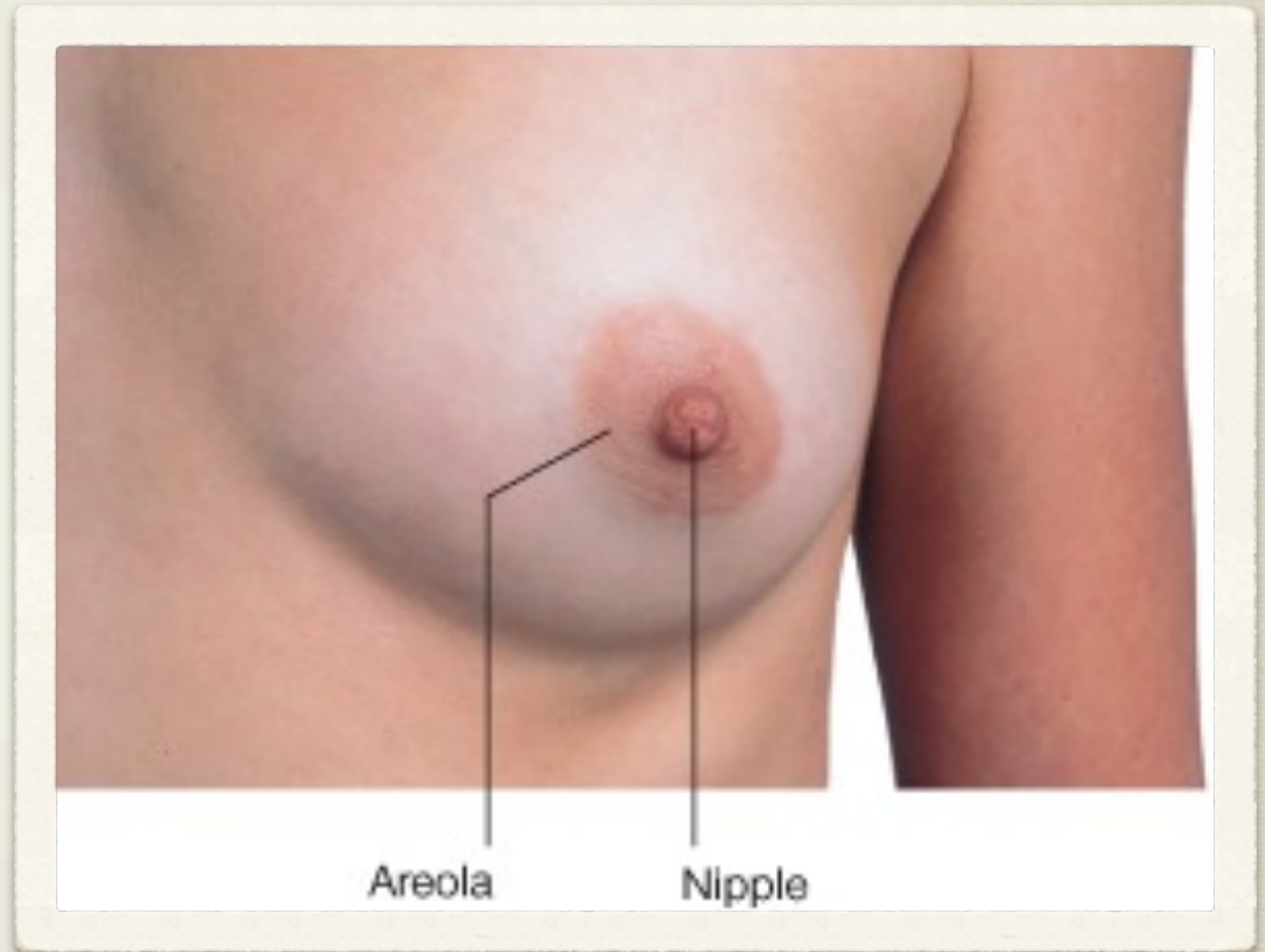






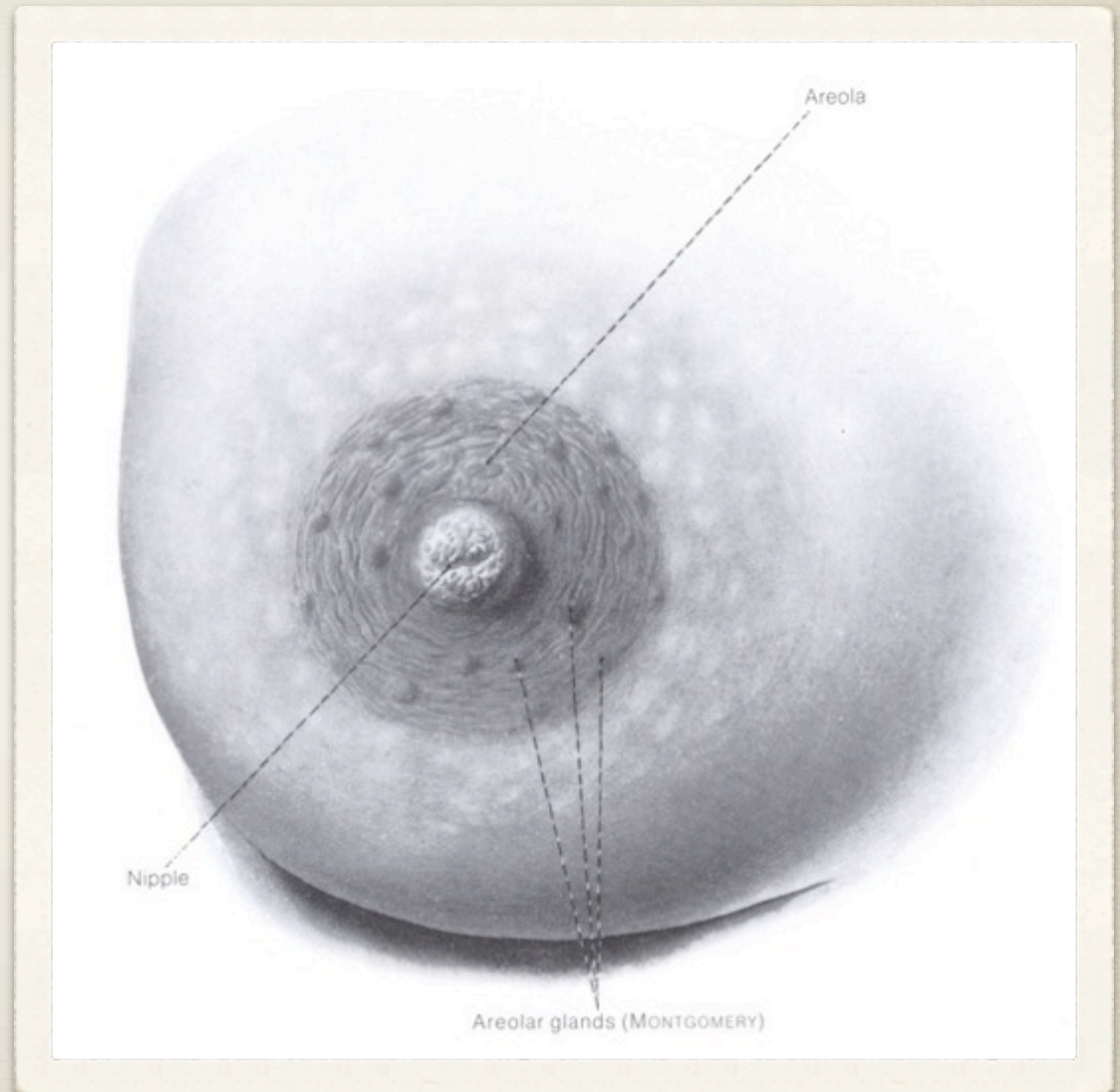
Meme Anatomisi – 3

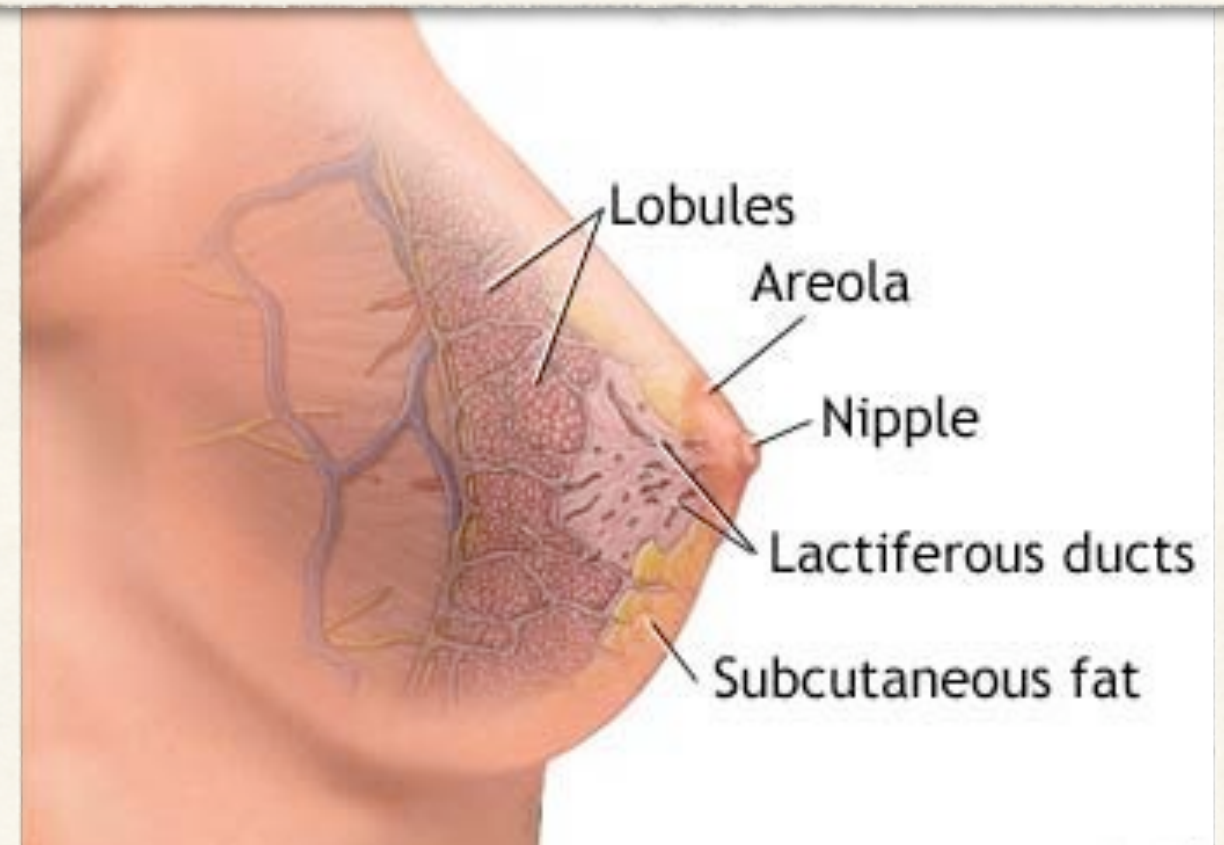
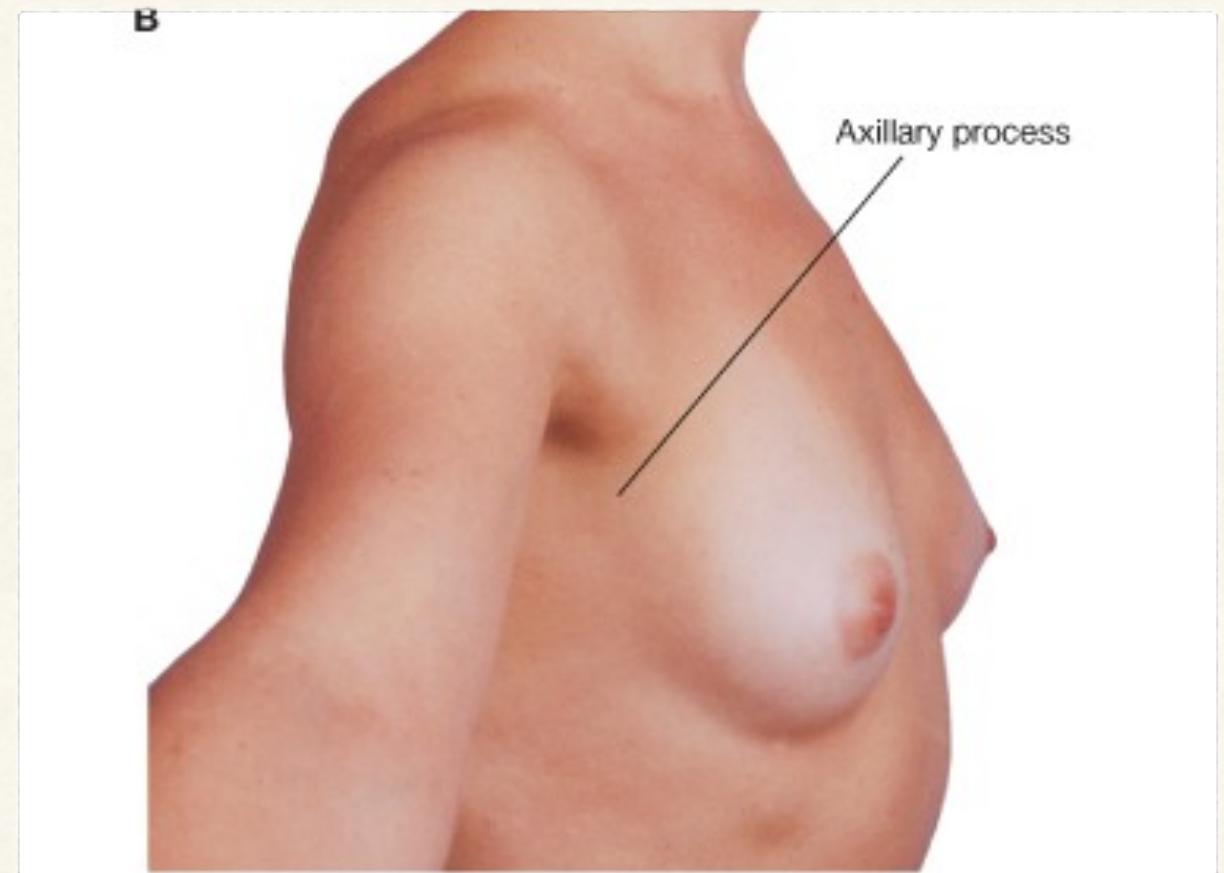
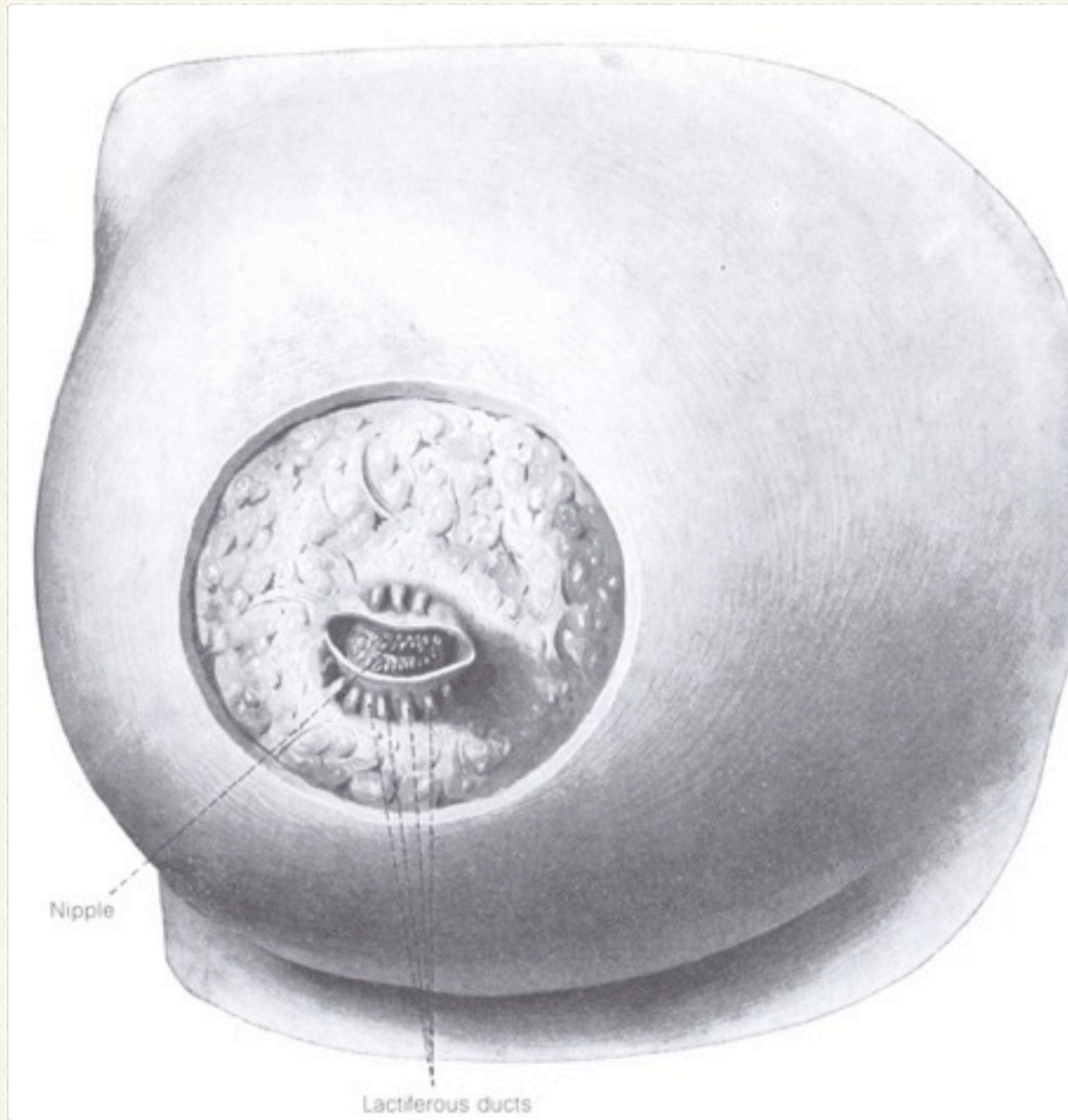
- * 150-200 gr
- * Corpus mammae
- * Sulcus mammarium (sinus mammarium)
- * Papilla mammaria – 4. interkostal aralık
- * Areola mammae

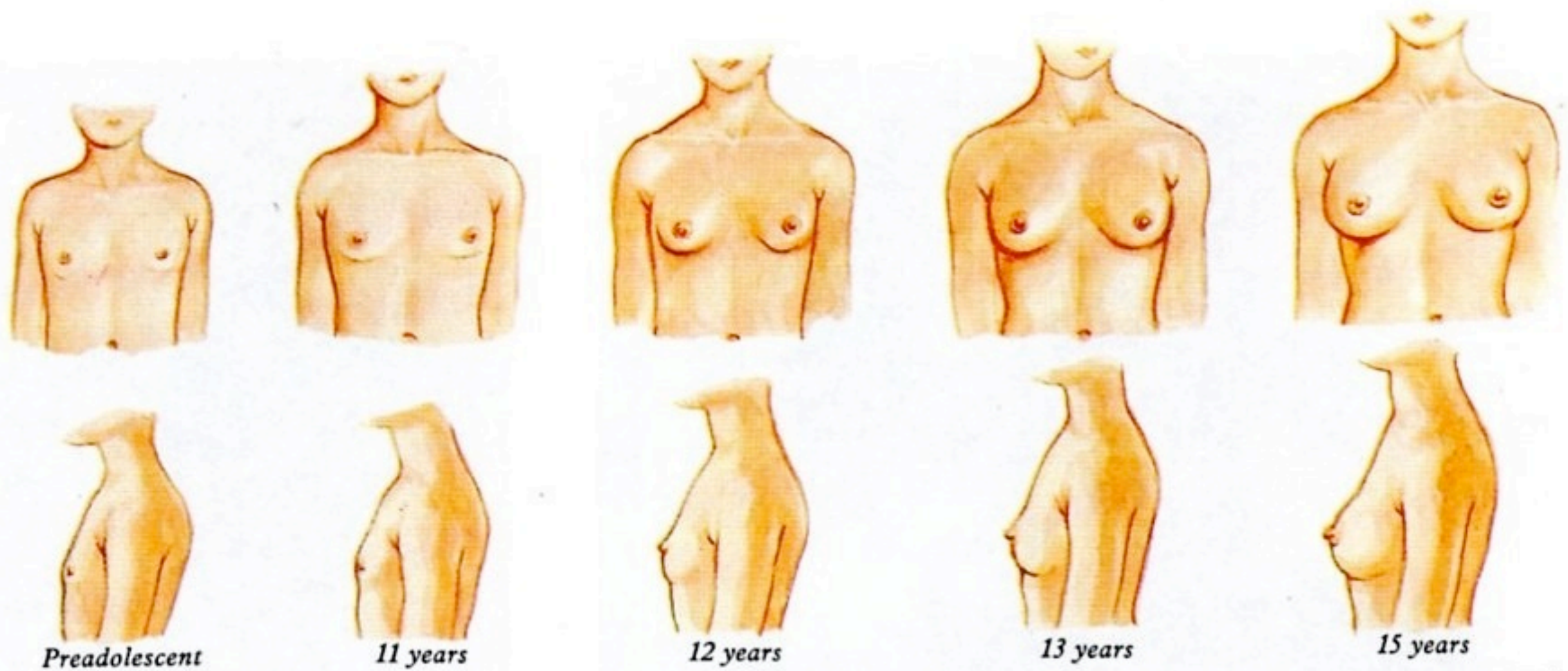


Meme Anatomisi – 4

- * Tubercula areolare (Montgomery)
- * Glandulae areolares
- * Polythelia
- * Polymastia
- * Amastia

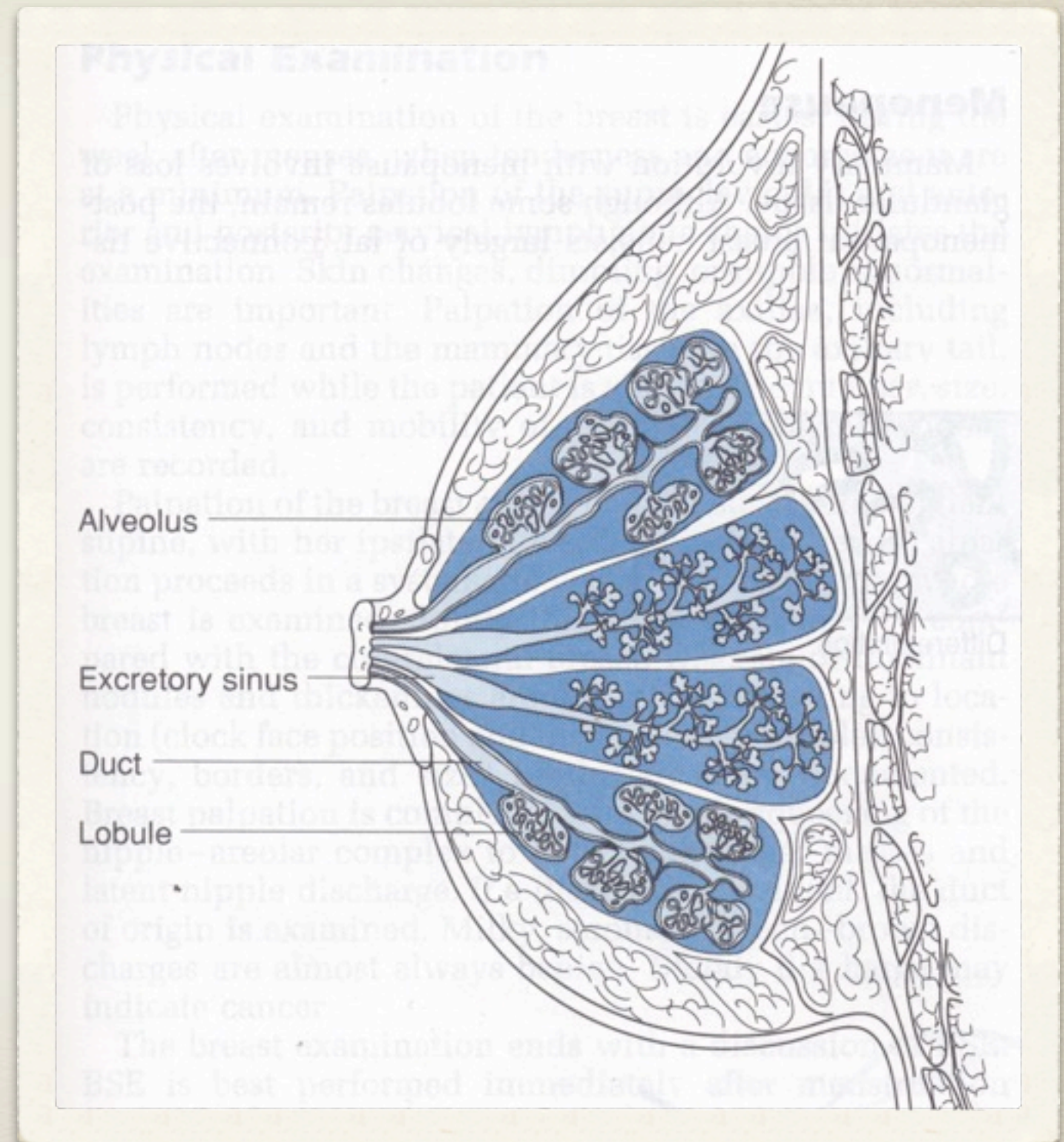






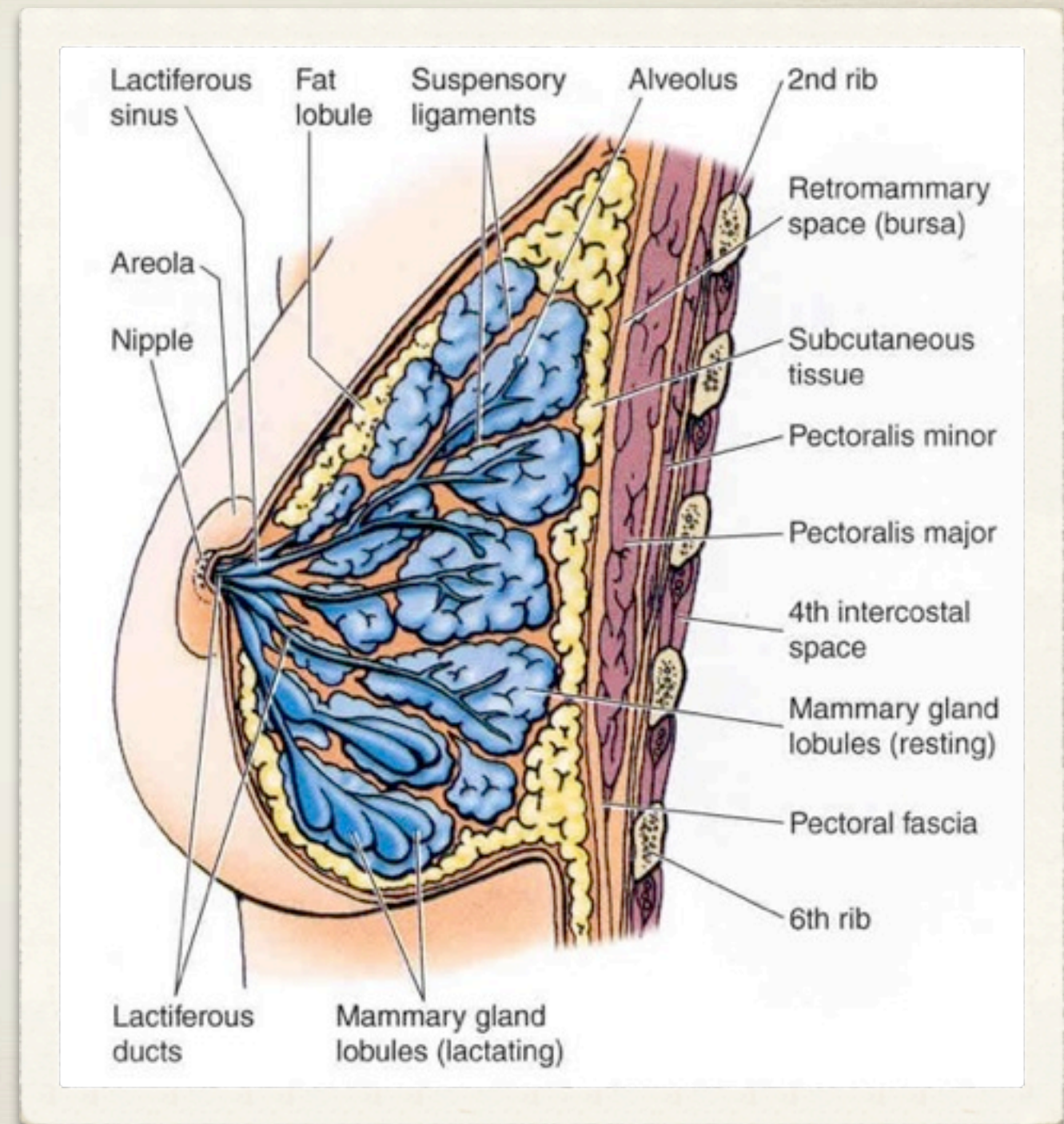
Meme Anatomisi – 5

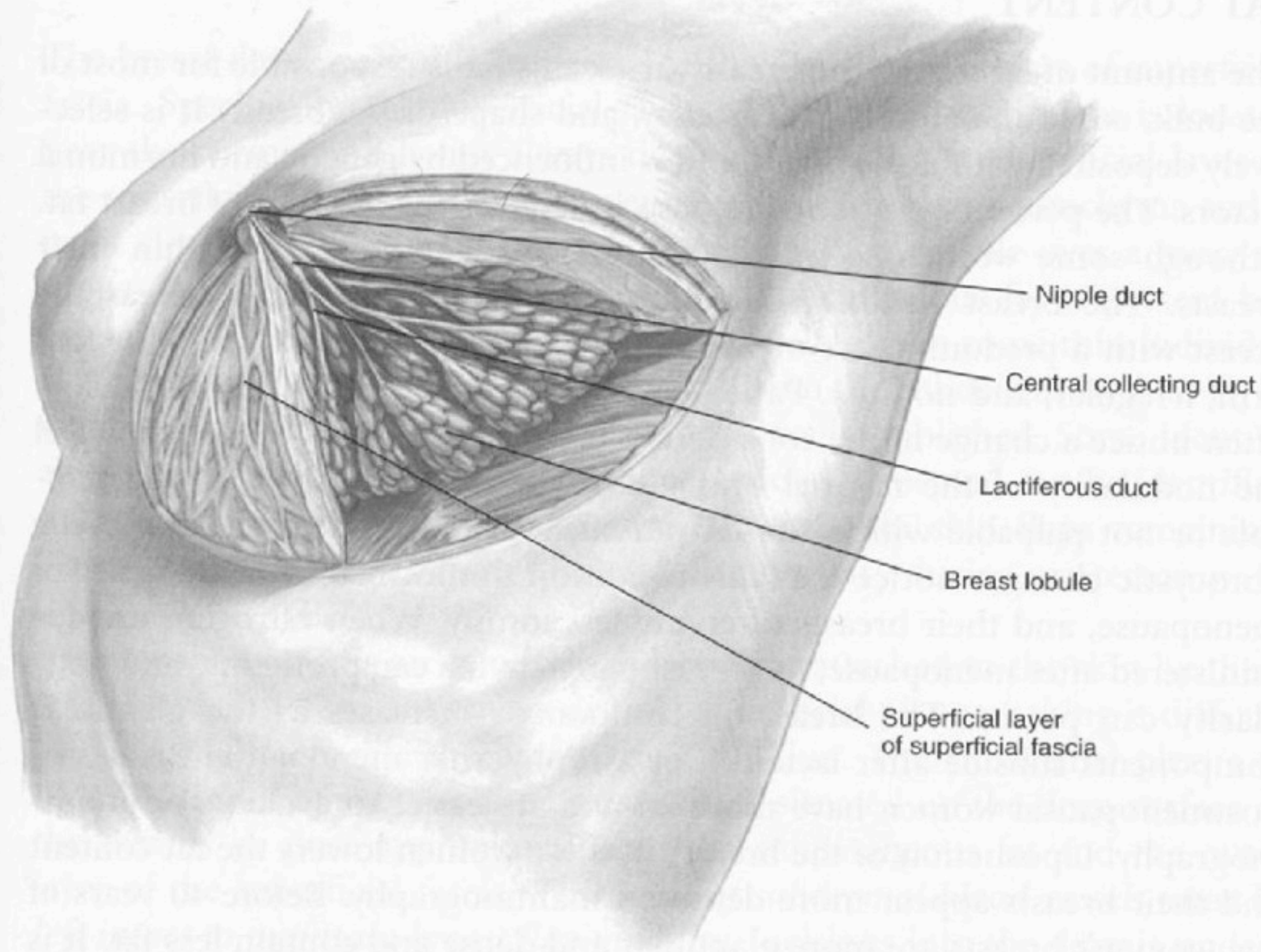
- * Bez + yağ + bağ
- * Ekzokrin
- * Tübüloalveoler
- * 15-20 lob
- * Lobi glandulae mammariae



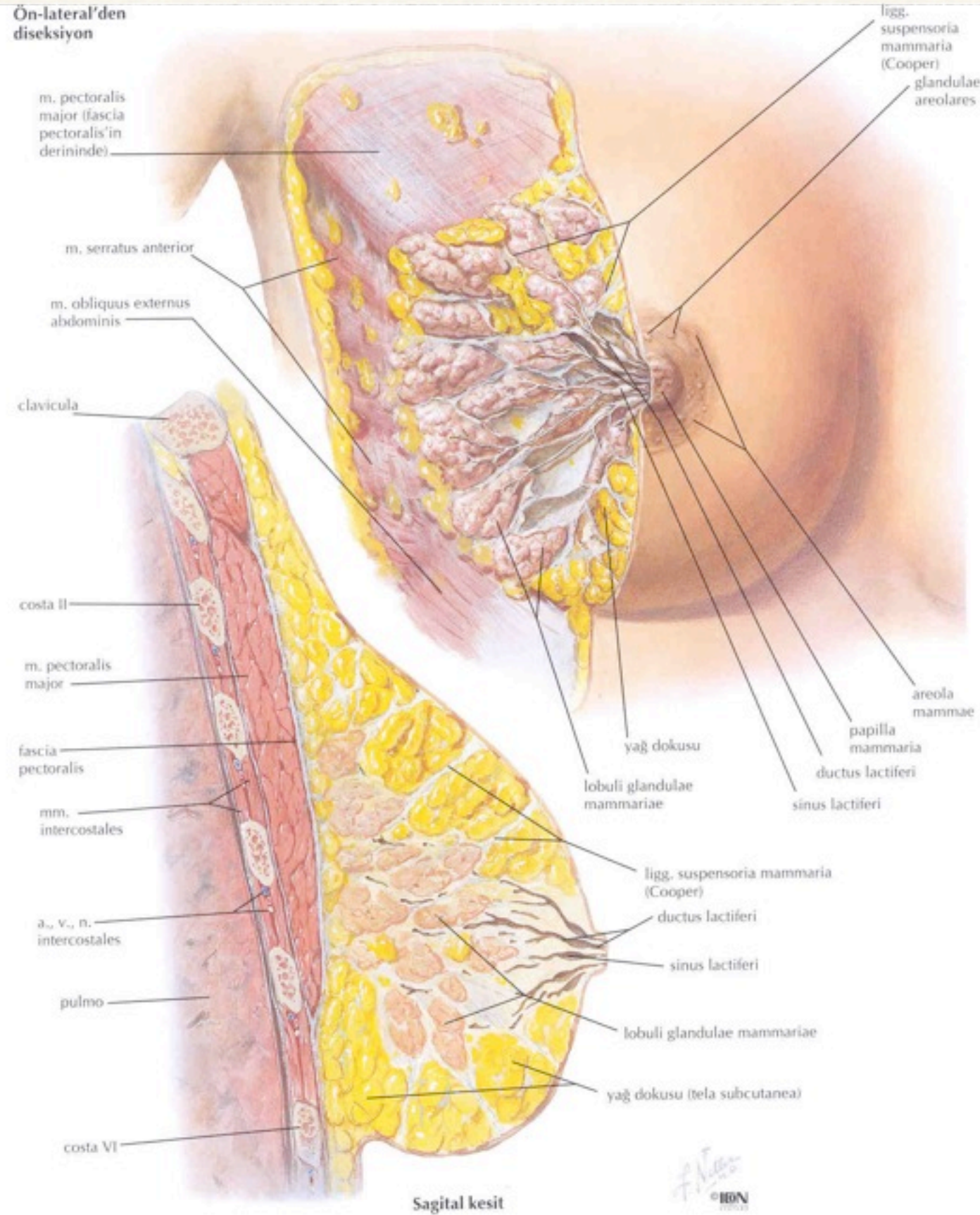
Meme Anatomisi – 6

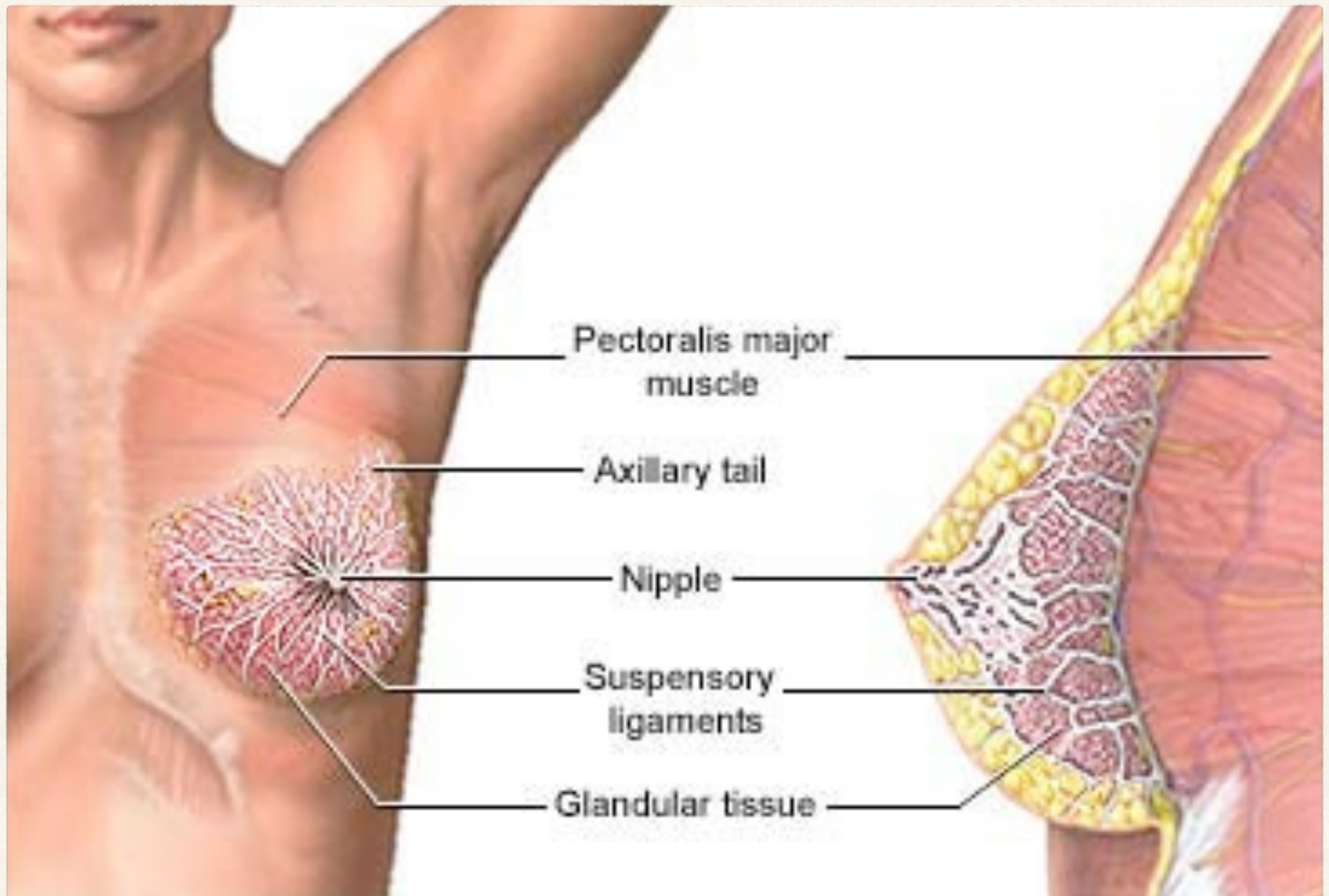
- * Ductus lactiferi
- * Sinus lactiferi
- * Ostium papillare
- * M. sphincter papilla
- * Ligg. suspensoria mammaria (Cooper)
– ductus ile dermis arası

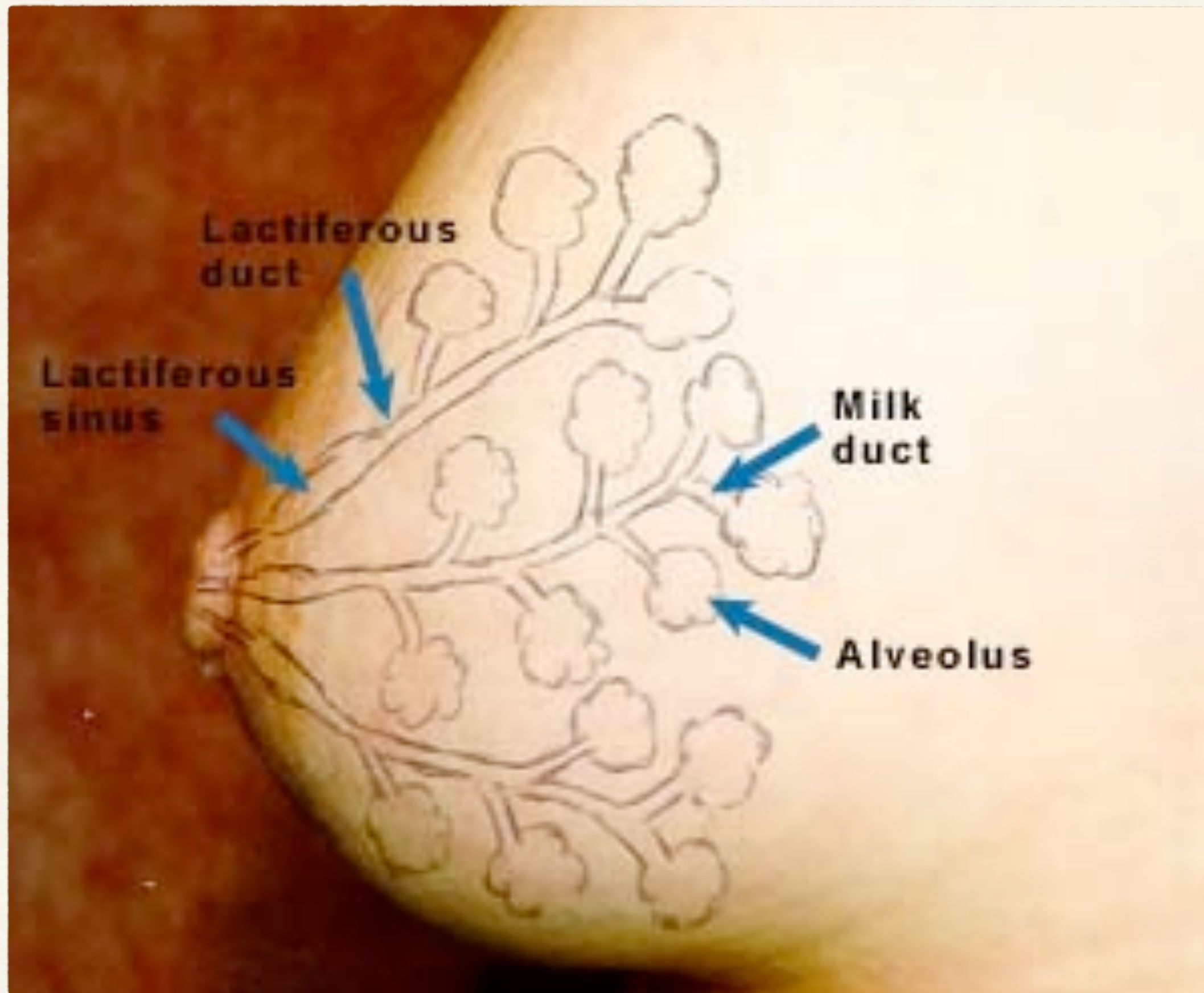




Ön-lateral'den
diseksiyon

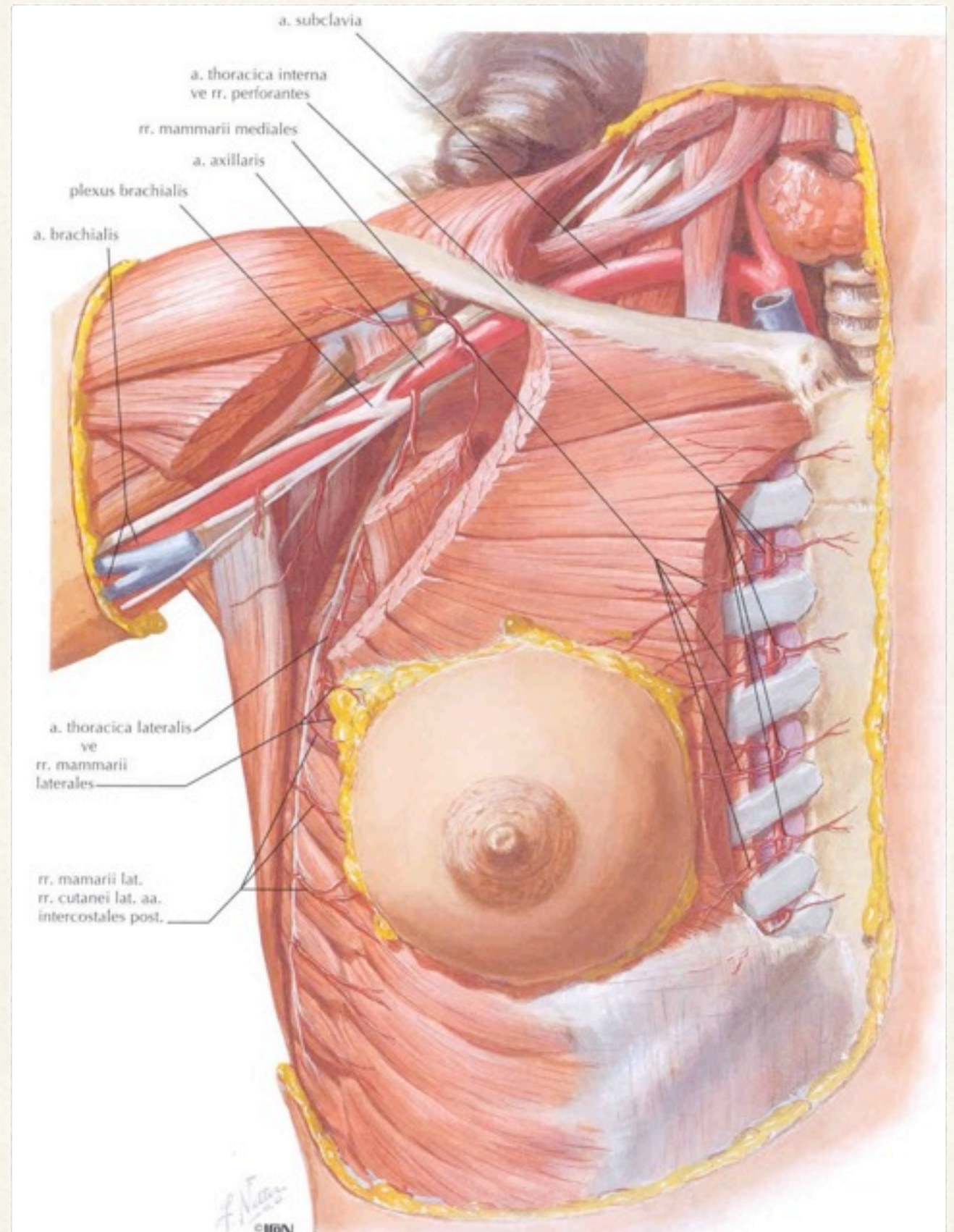






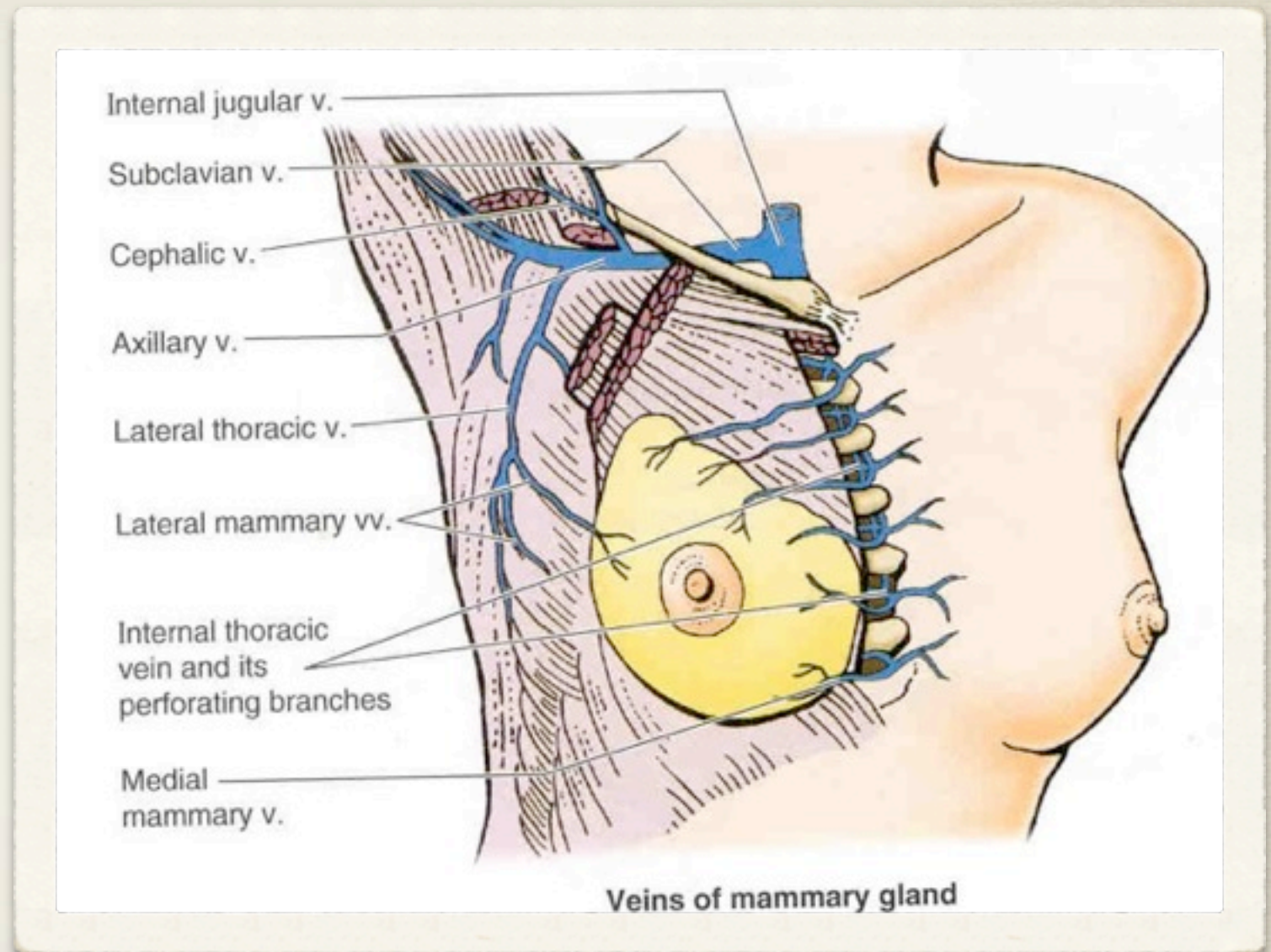
Arterleri

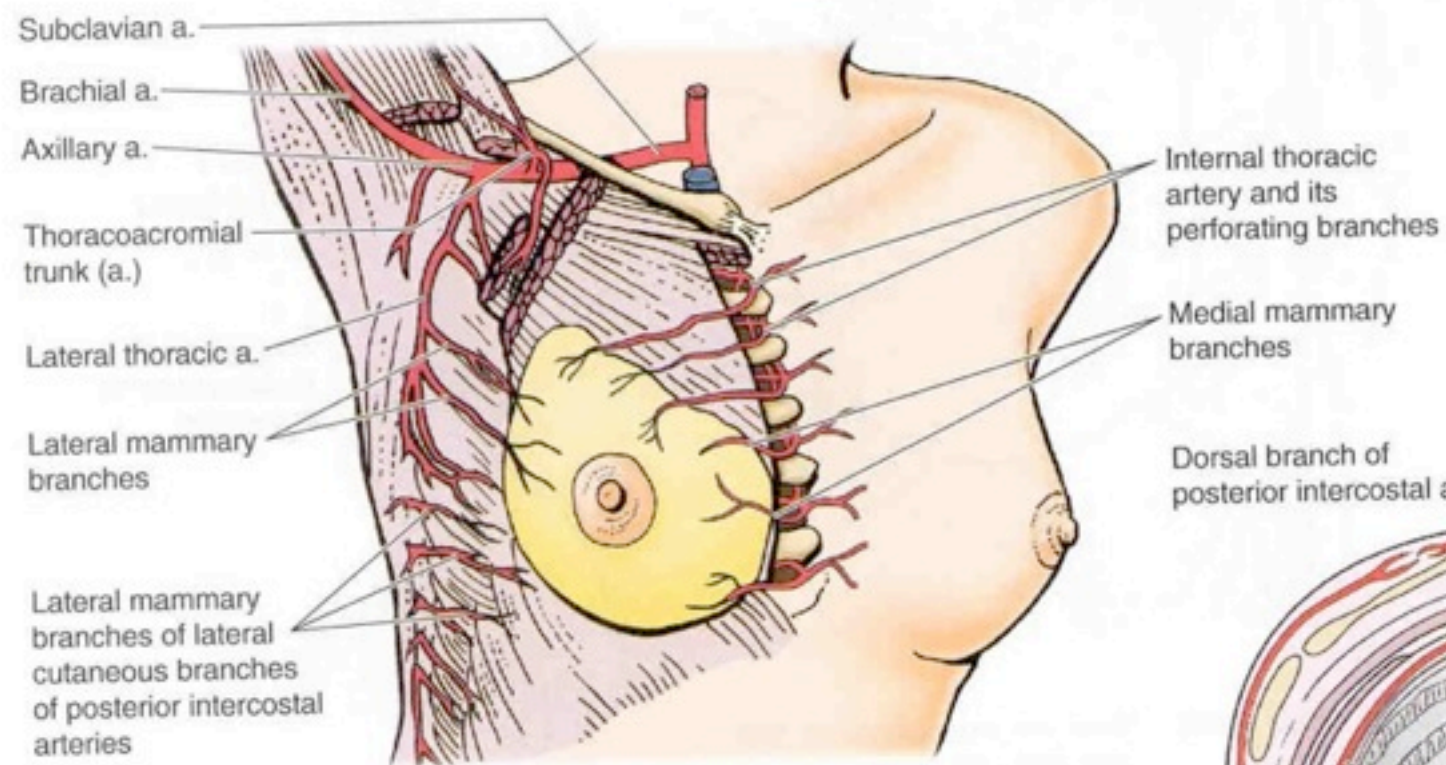
- * Rr. mammarii laterales (2-4 a. intercostalis post. / a. thoracica lat.)
- * Rr. mammarii mediales (a. thoracica interna'nın perforan dallarından)
- * A. thoraco-acromialis (a. axillaris)
- * 2-4 a. intercostalis ant.



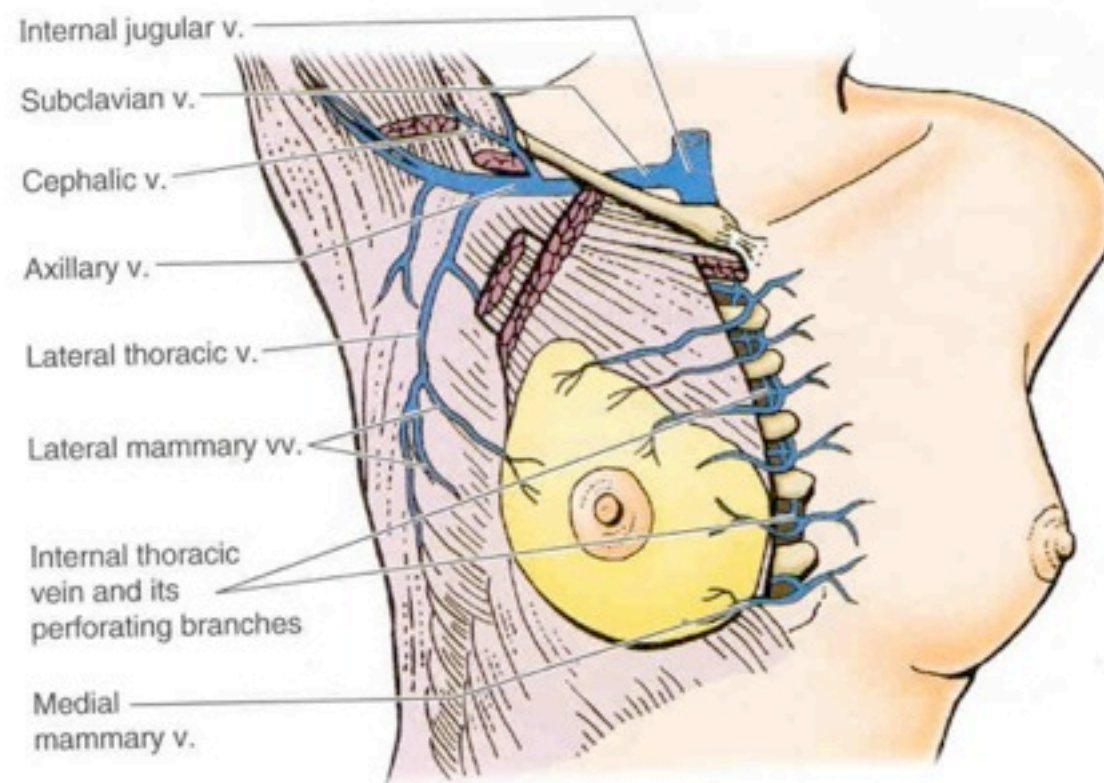
Venleri & İnervasyon

- * Yüzeyel venleri – v. thoracica interna'ya
- * Derin venleri – v. axillaris, vv. intercostales, v. thoracica interna
- * 2–6 nn. intercostales – r. cutaneus ant. / lat.
- * N. supraclavicularis

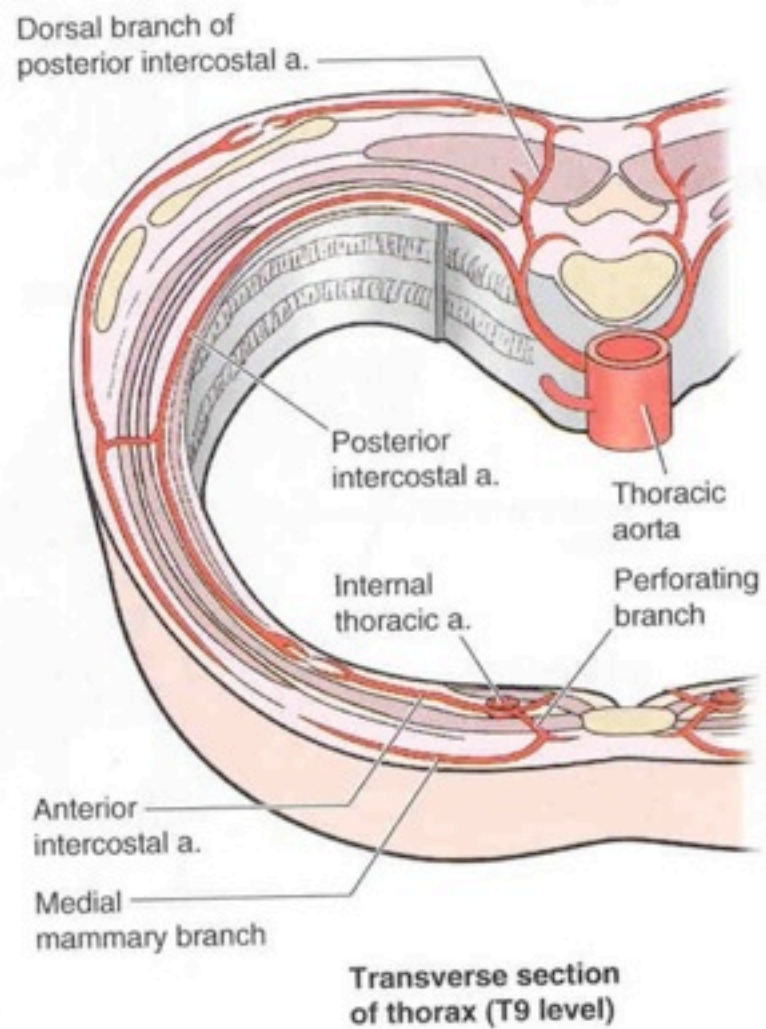


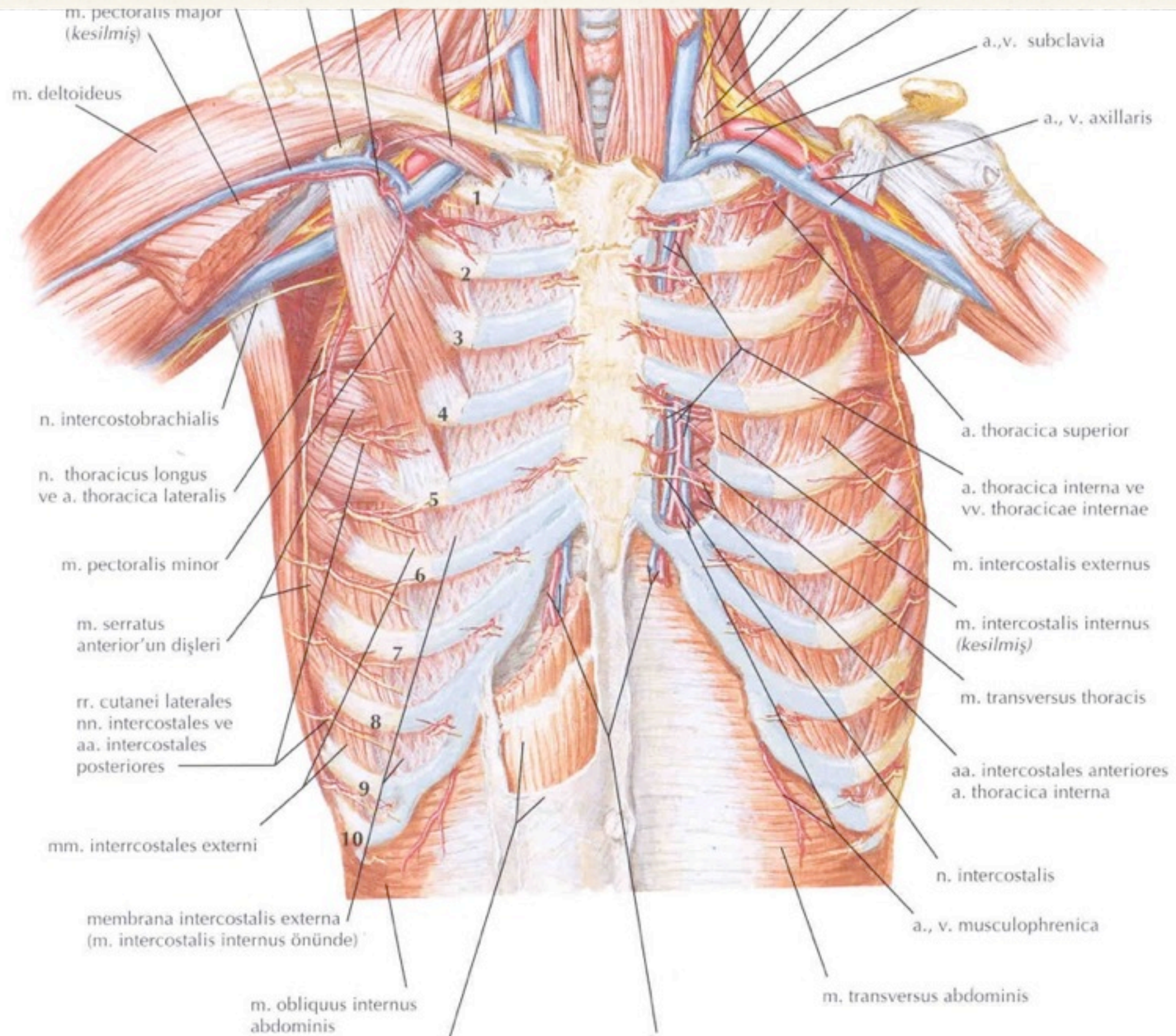


Arteries of mammary gland



Veins of mammary gland





Lenfatik Drenaj

- * %75: axilla

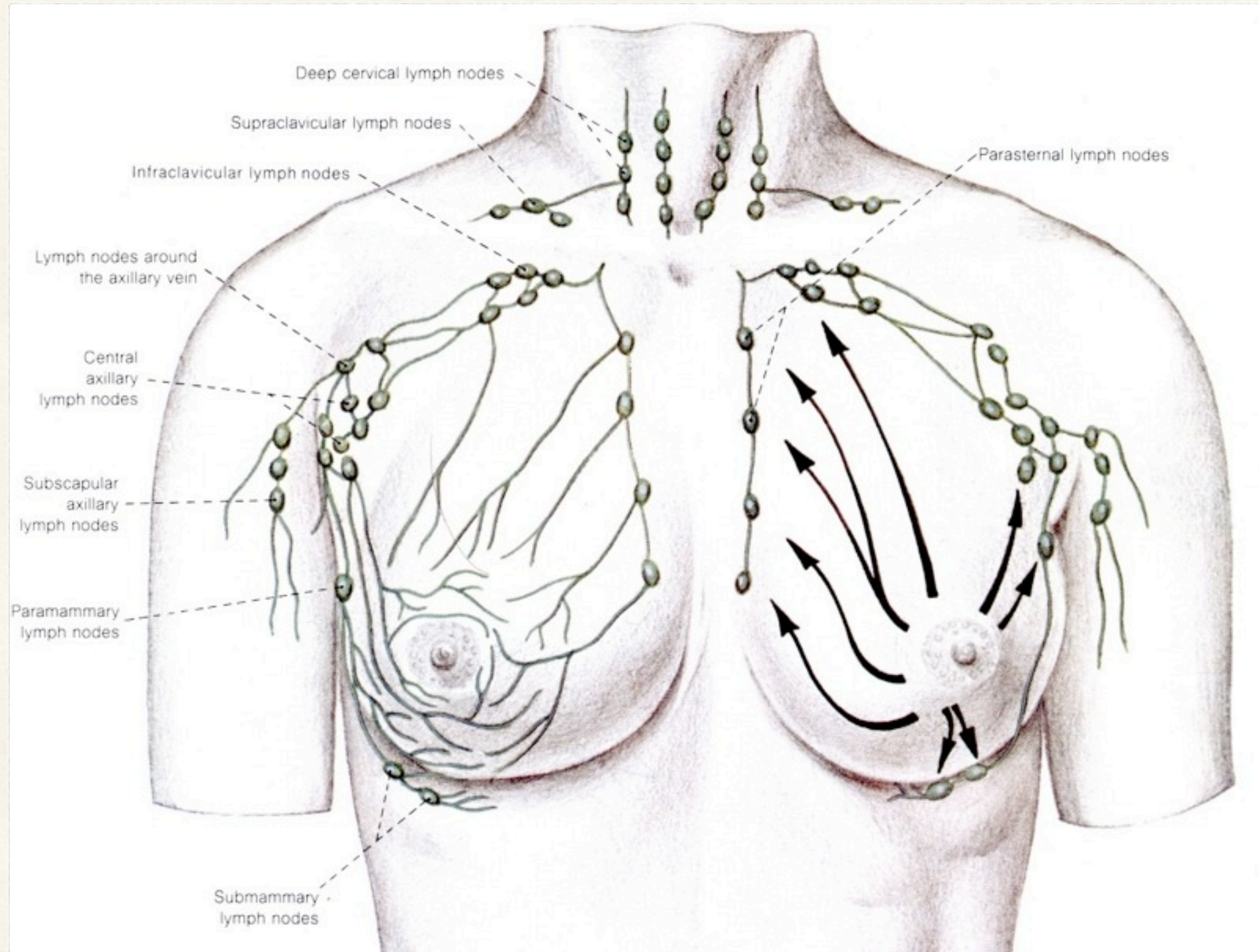
- * nodi lymphatici pectorales

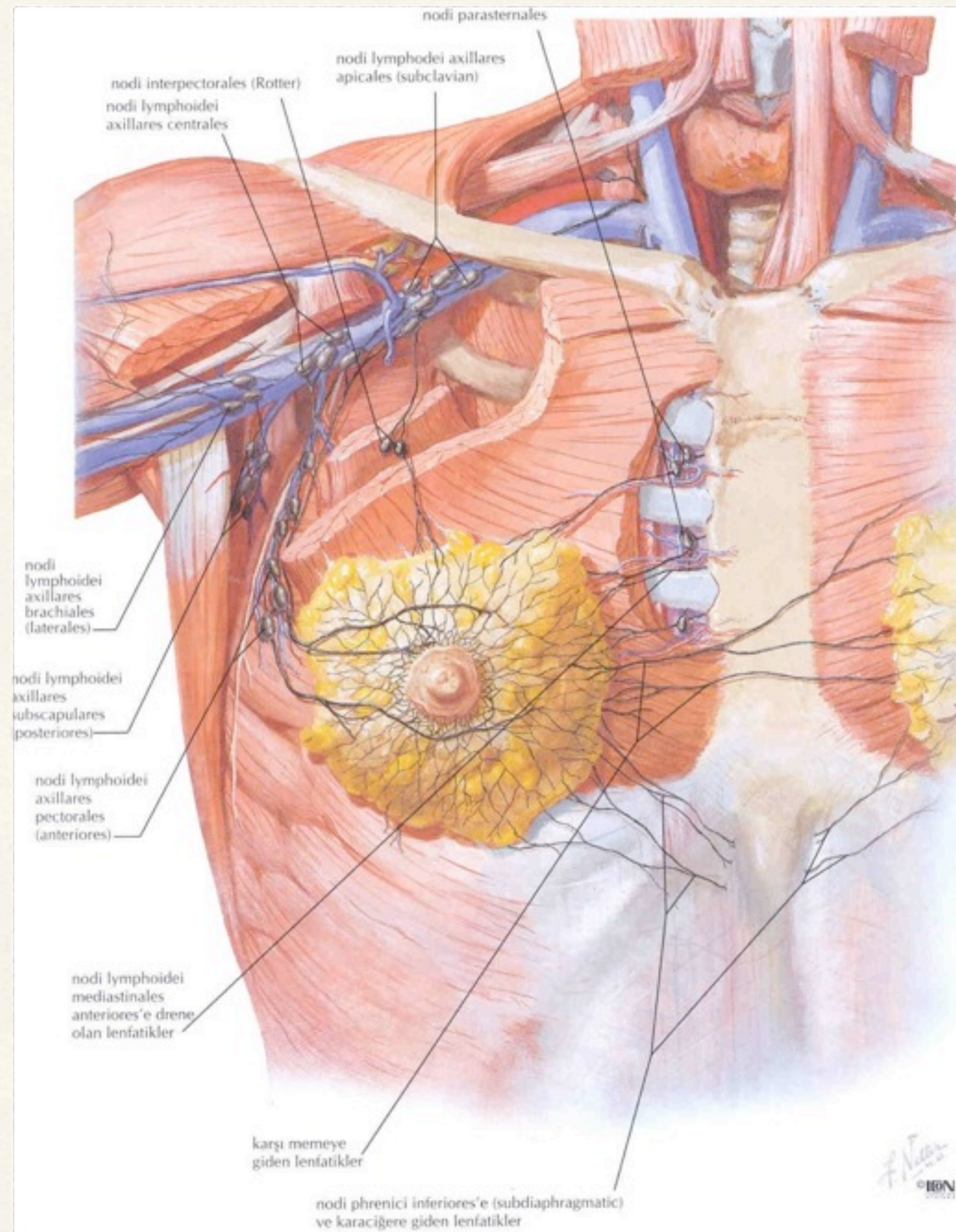
- * nodi lymphatici subscapulares

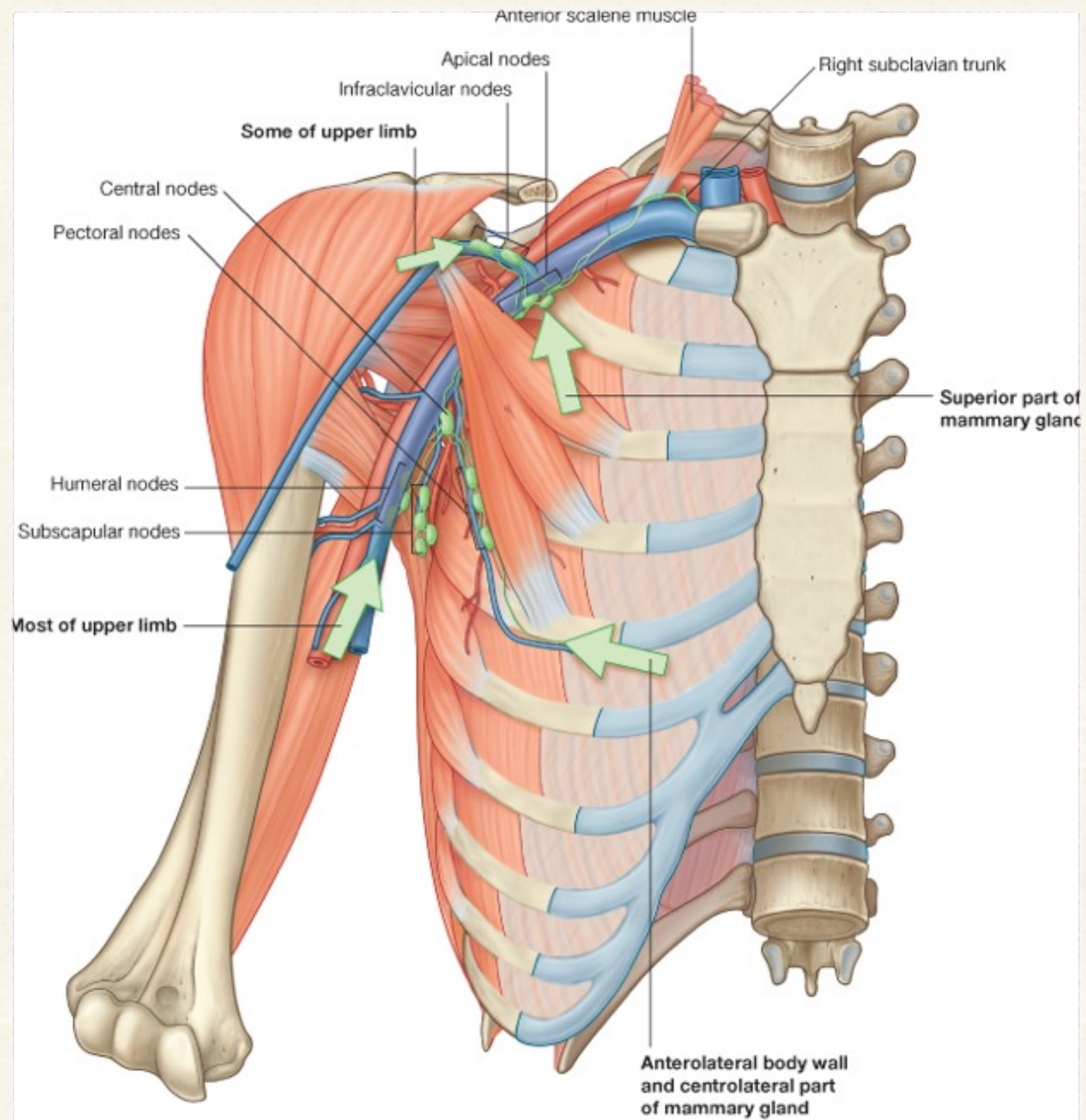
- * Geri kalanı a. thoracica interna çevresindeki:

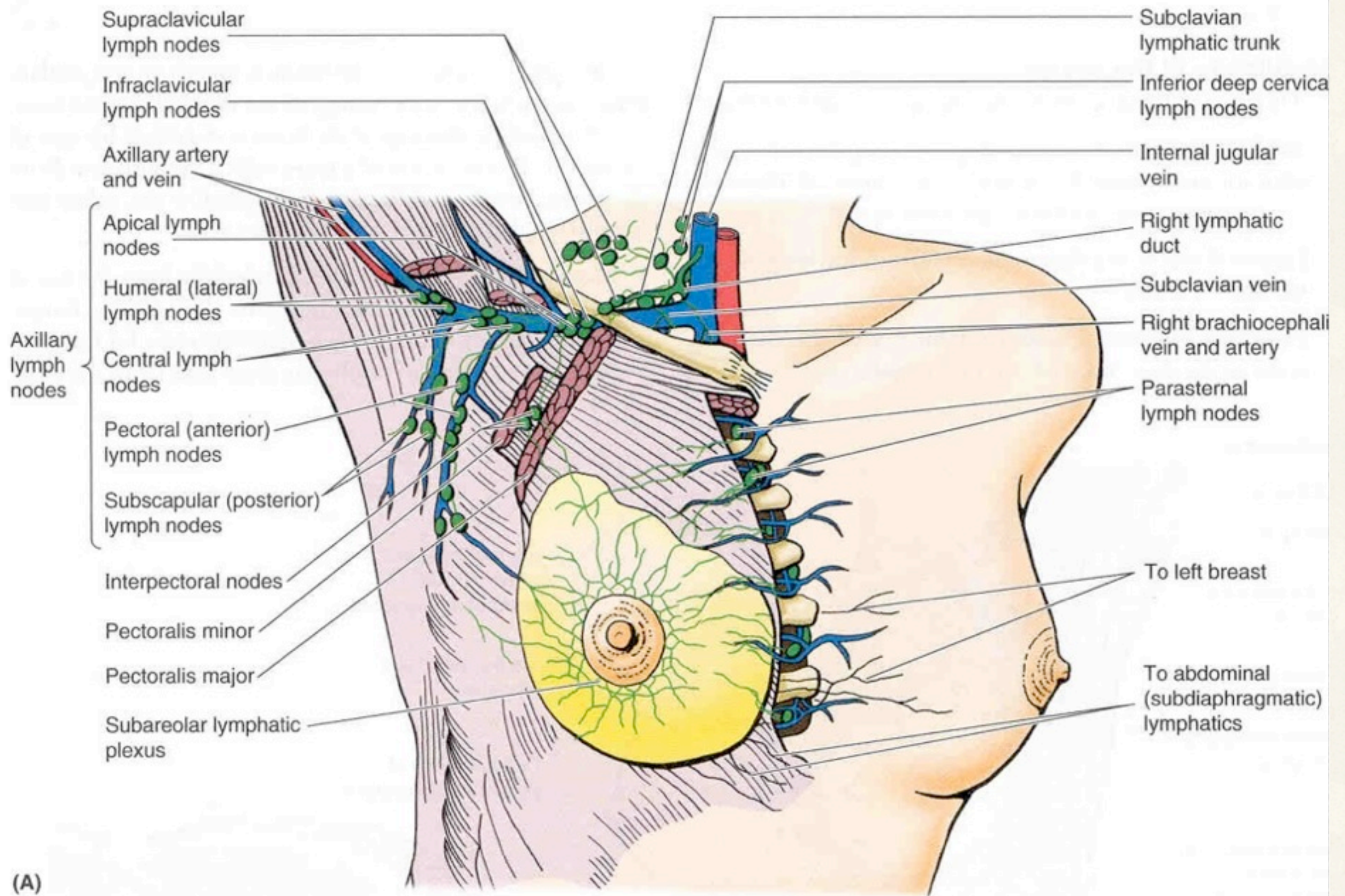
- * nodi lymphatici parasternales (internal mammarian)

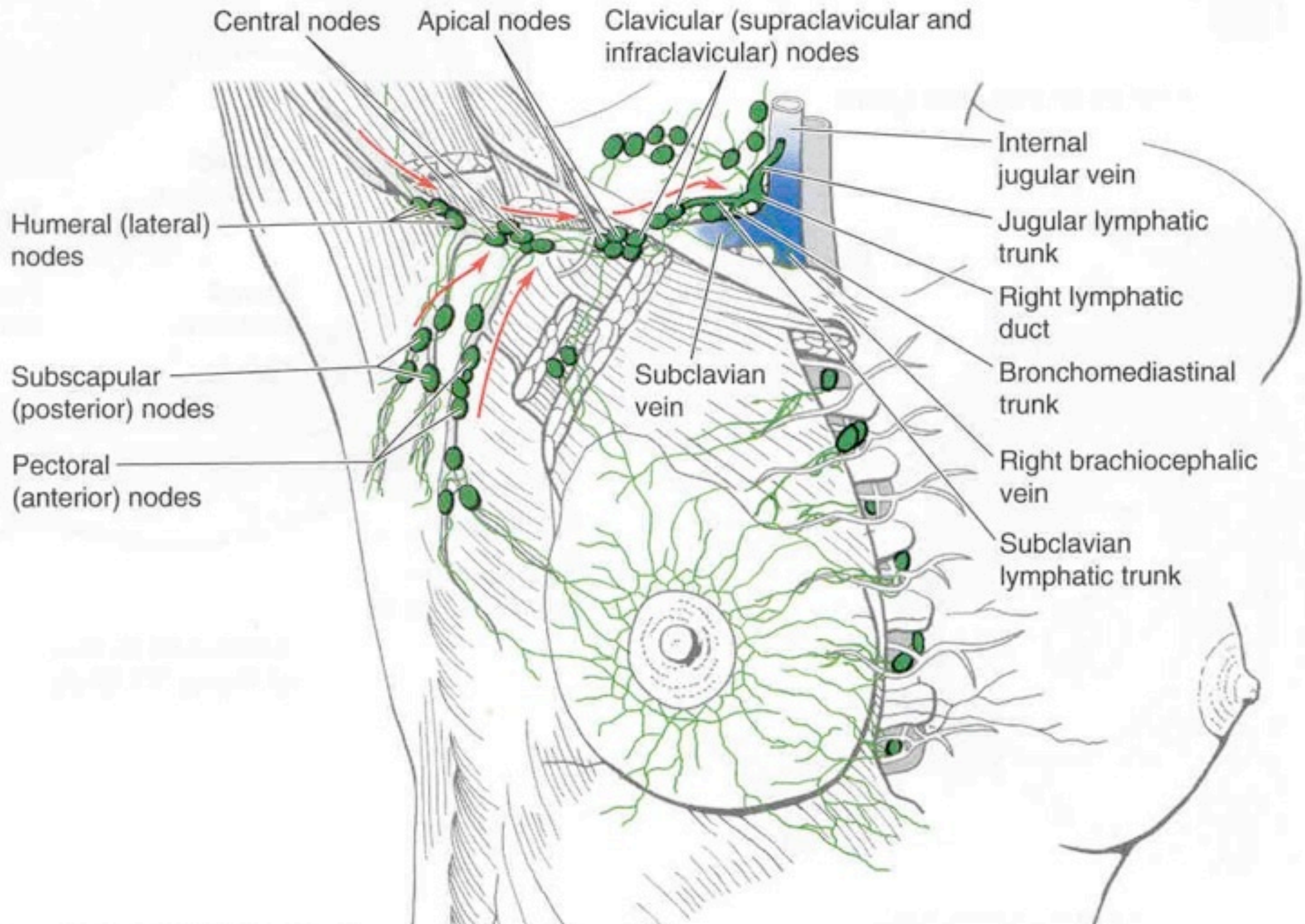
- * nodi lymphatici intercostales







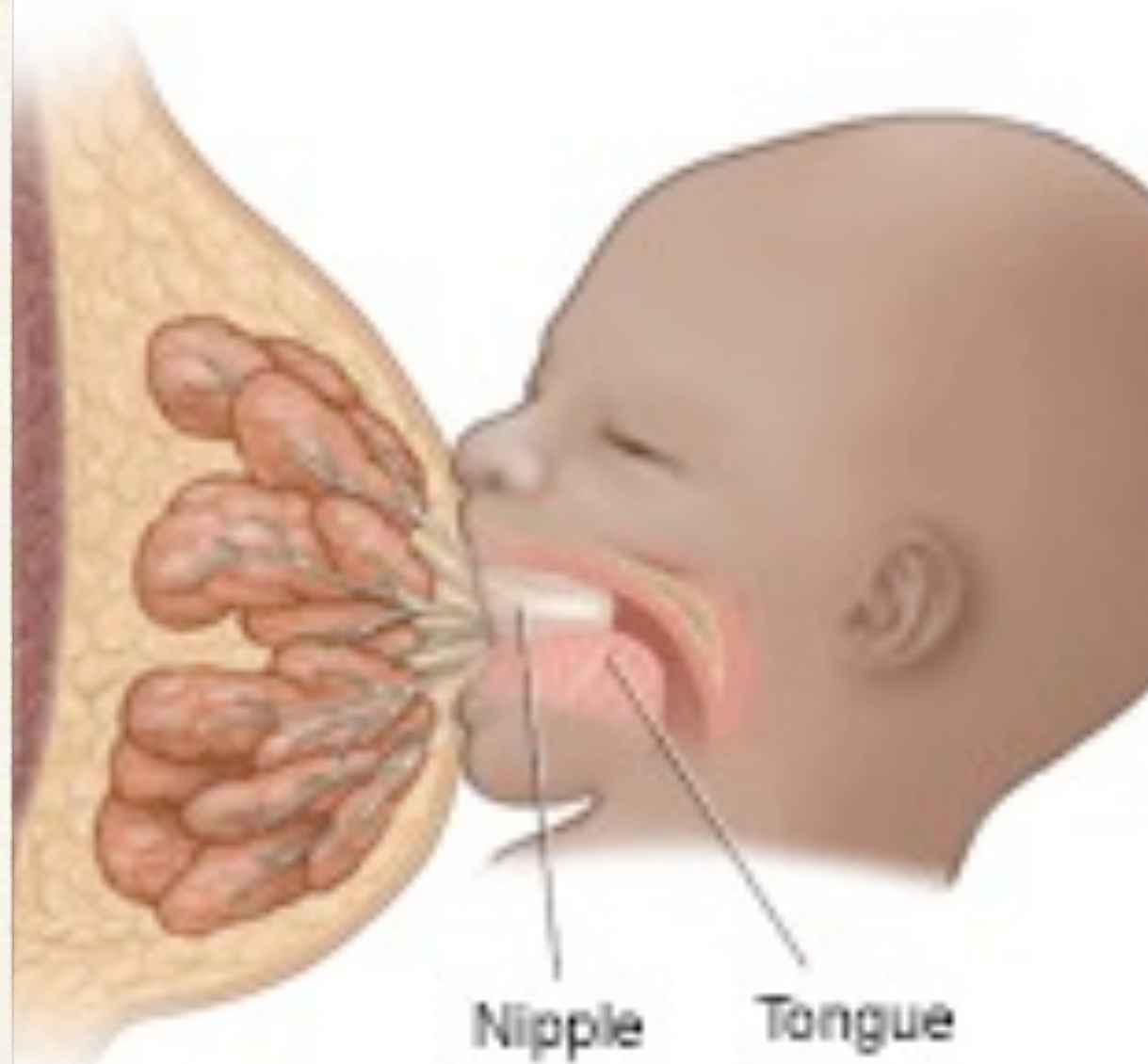




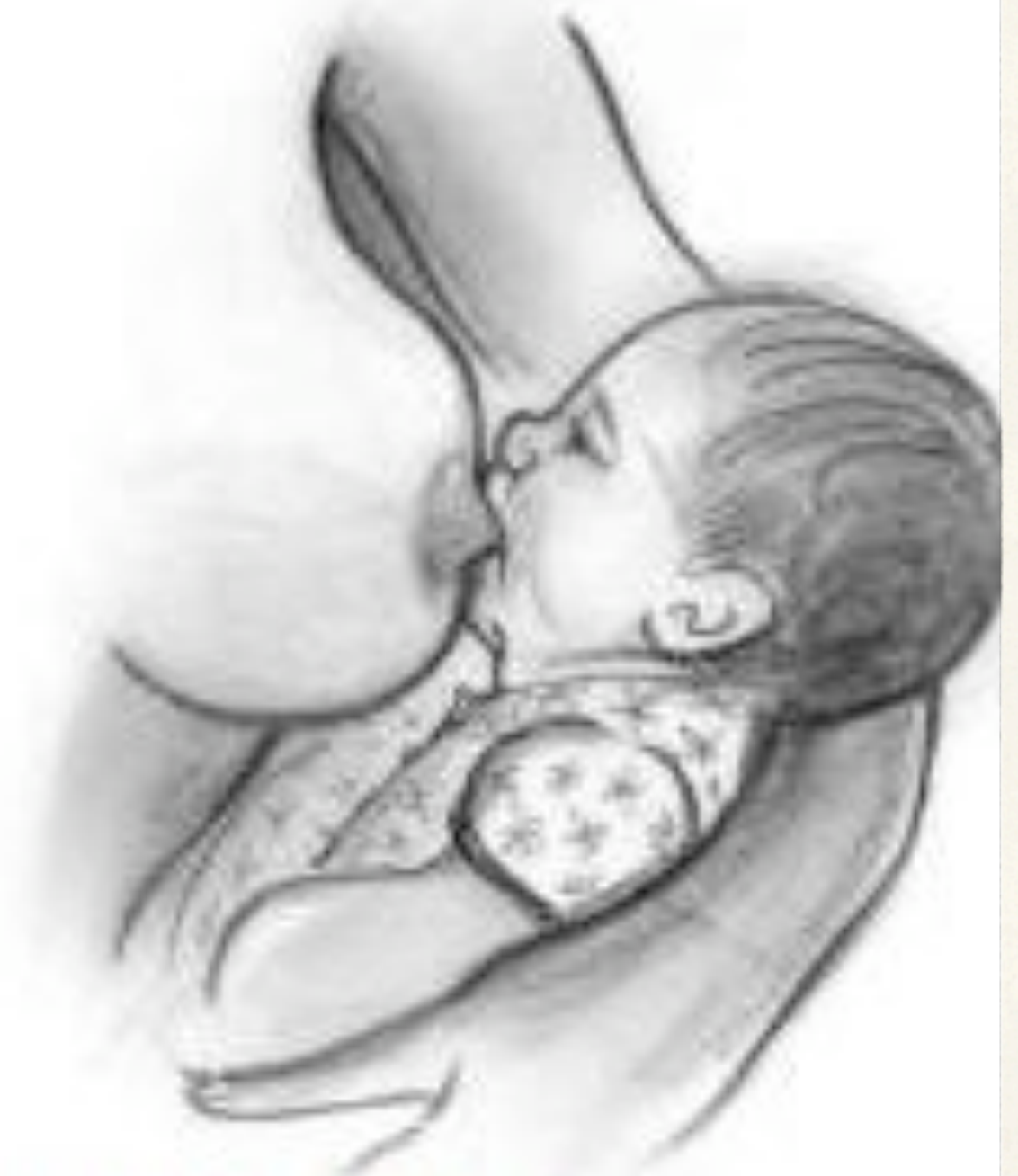Klinik – 1

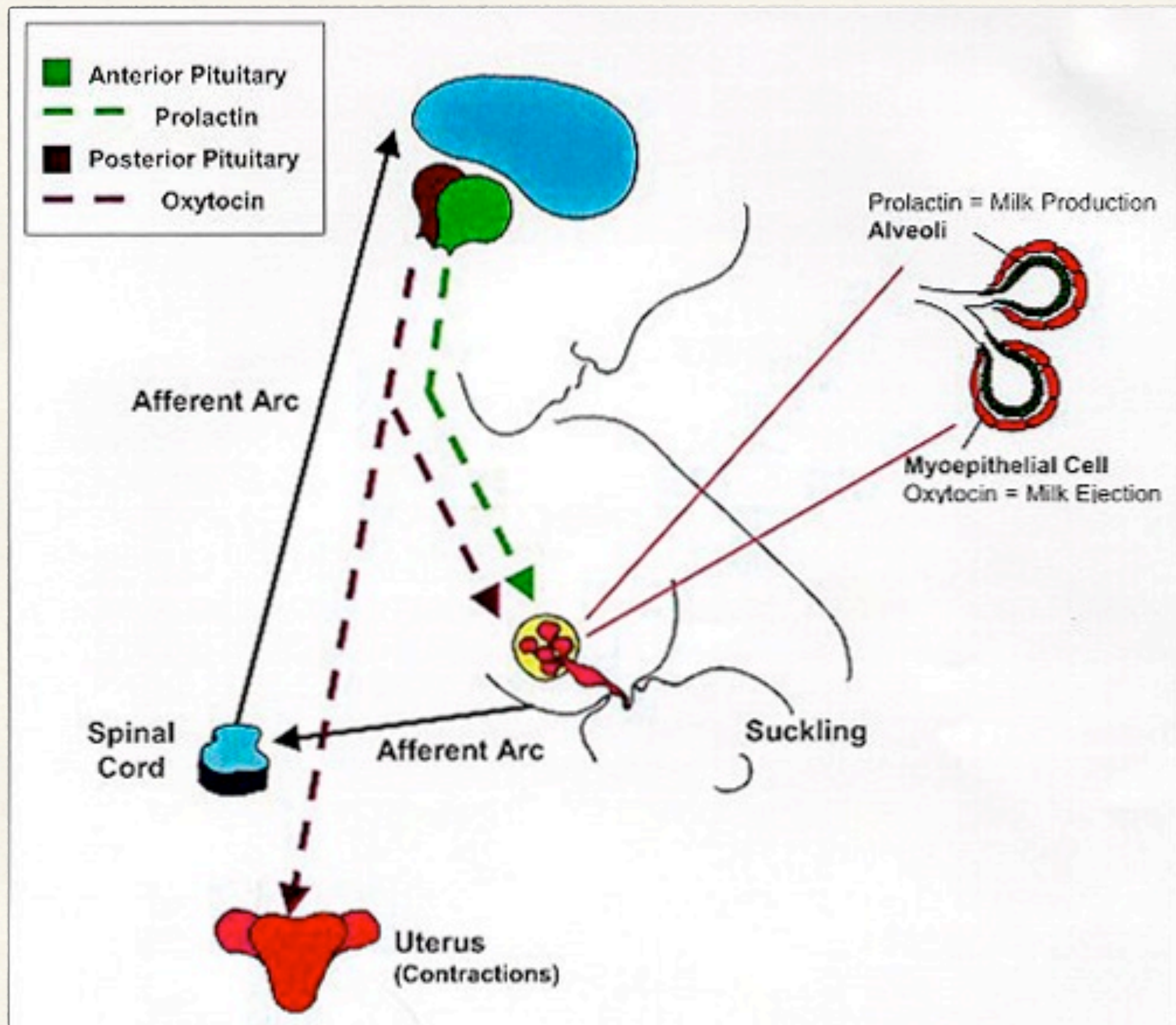
- * Colostrum
- * Fibroadenom
- * İnfiltratif duktal ca.
- * Sentinel lenf nodu
- * Kor / insizyonel / eksizyonel biyopsi
Lumpektomi
- * Basit mastektomi
- * Modifiye radikal mastektomi (meme+lenf)
- * Radikal mastektomi (meme+lenf+fascia+kas)
- * Gynecomastia

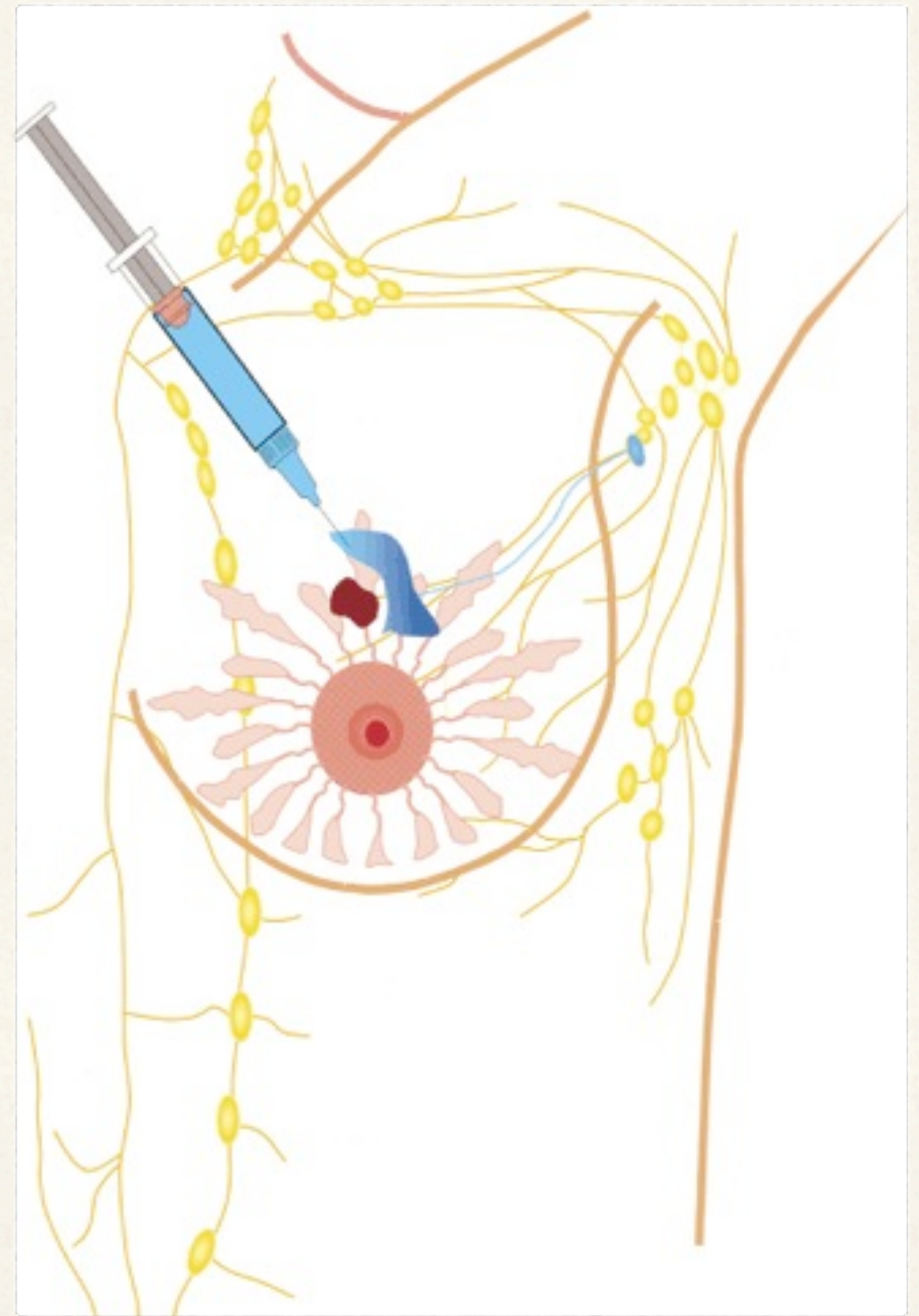
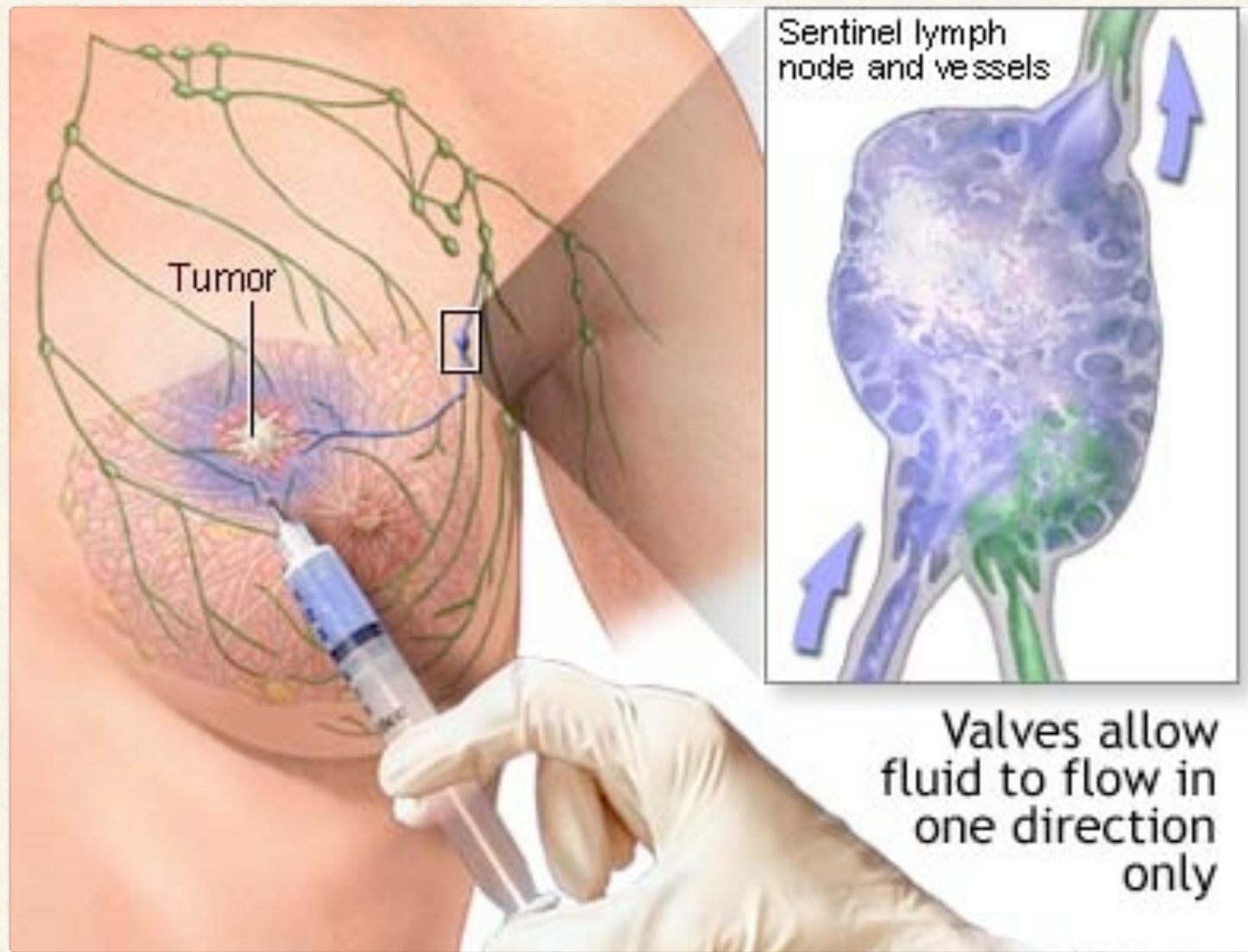
Deep Latch-on

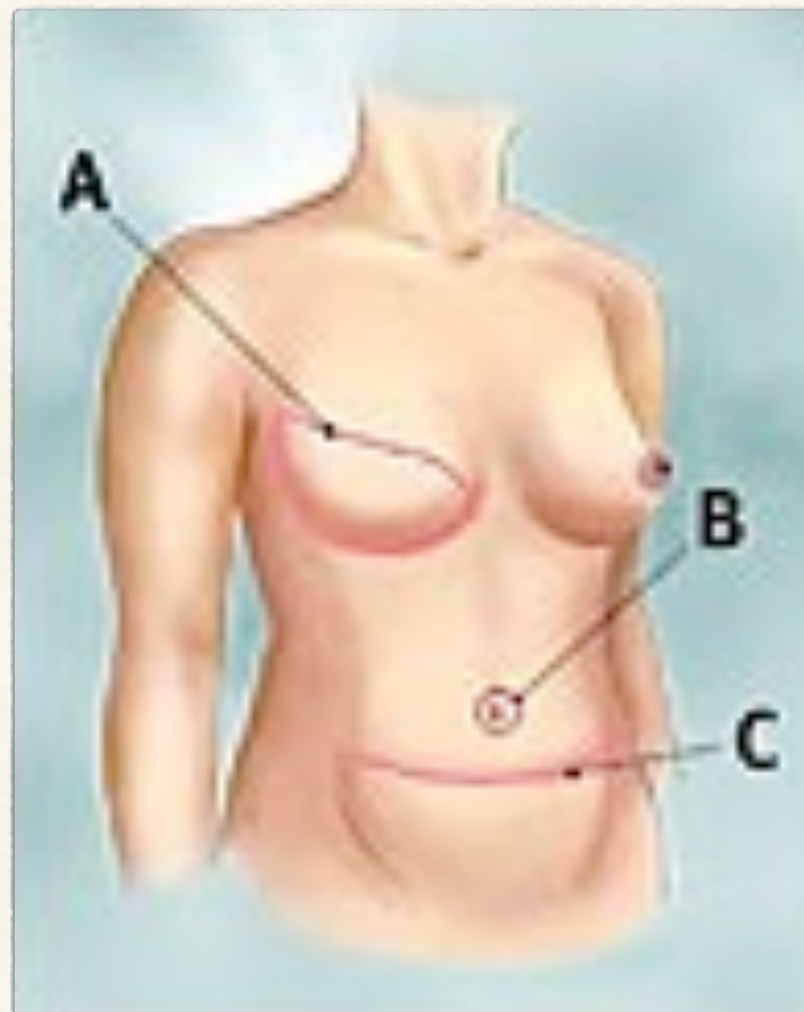
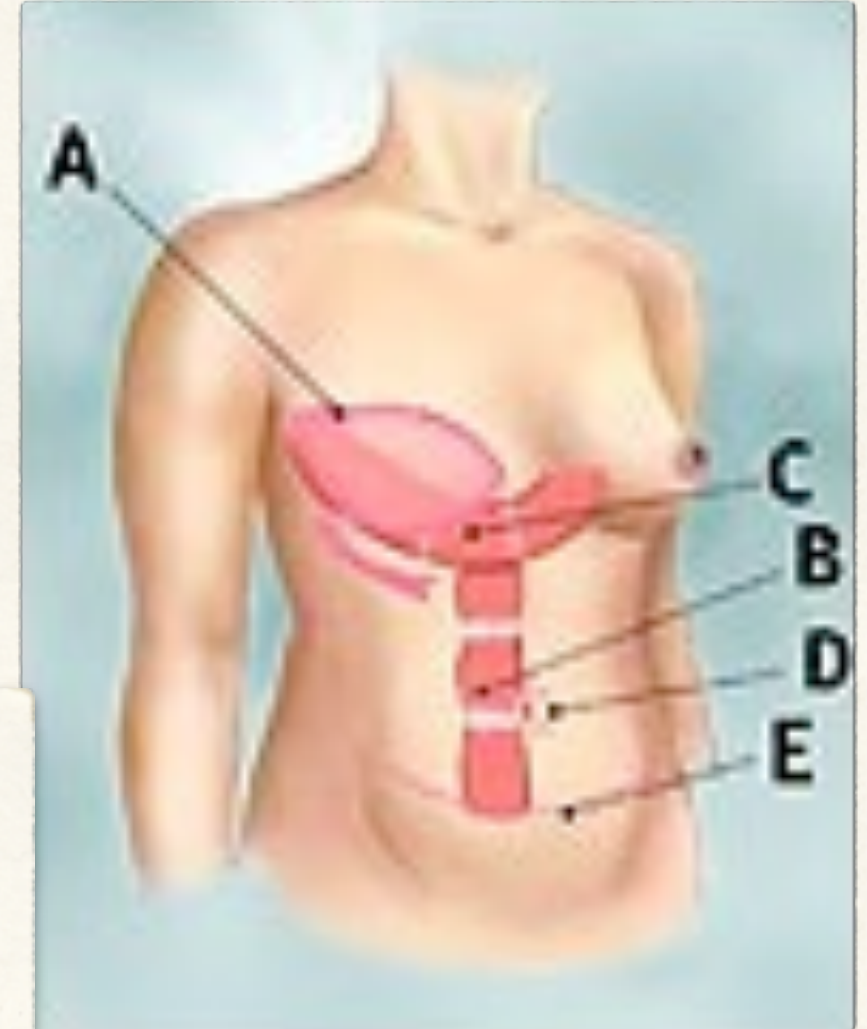
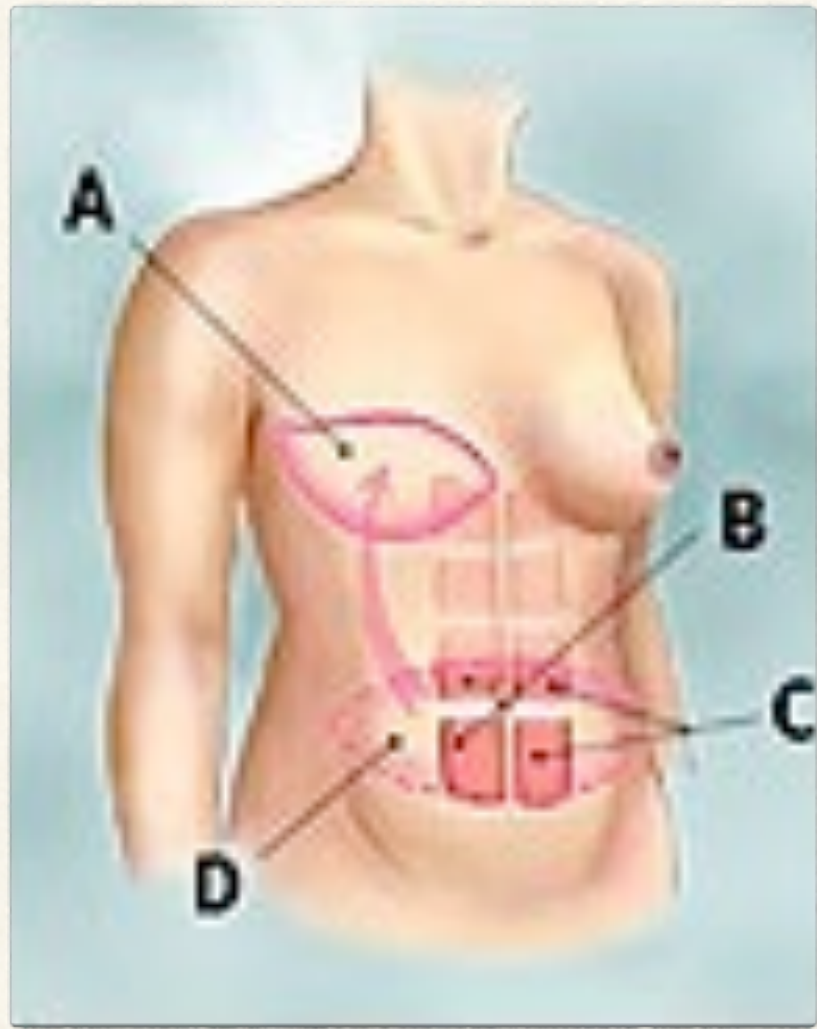


Improper Latch



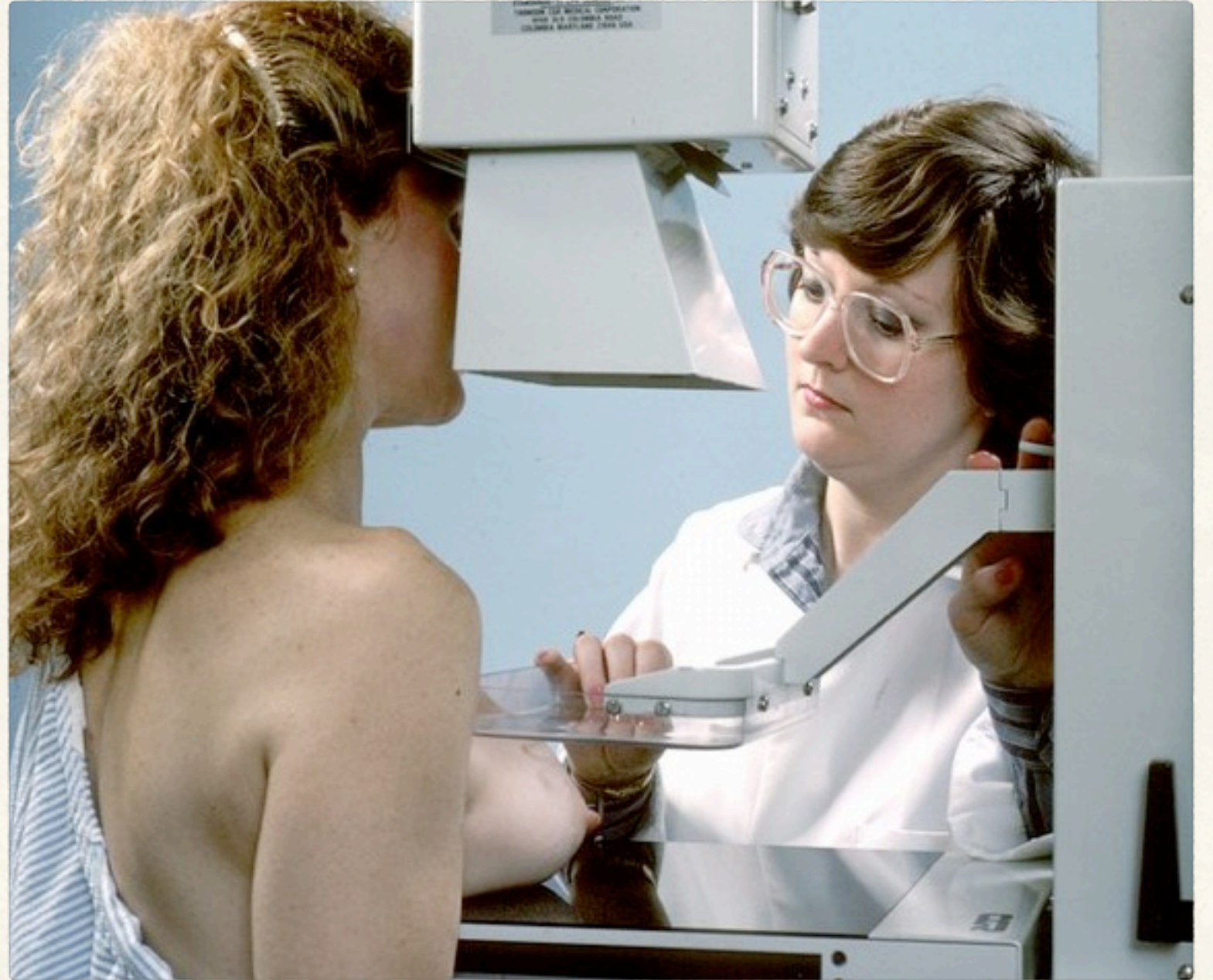

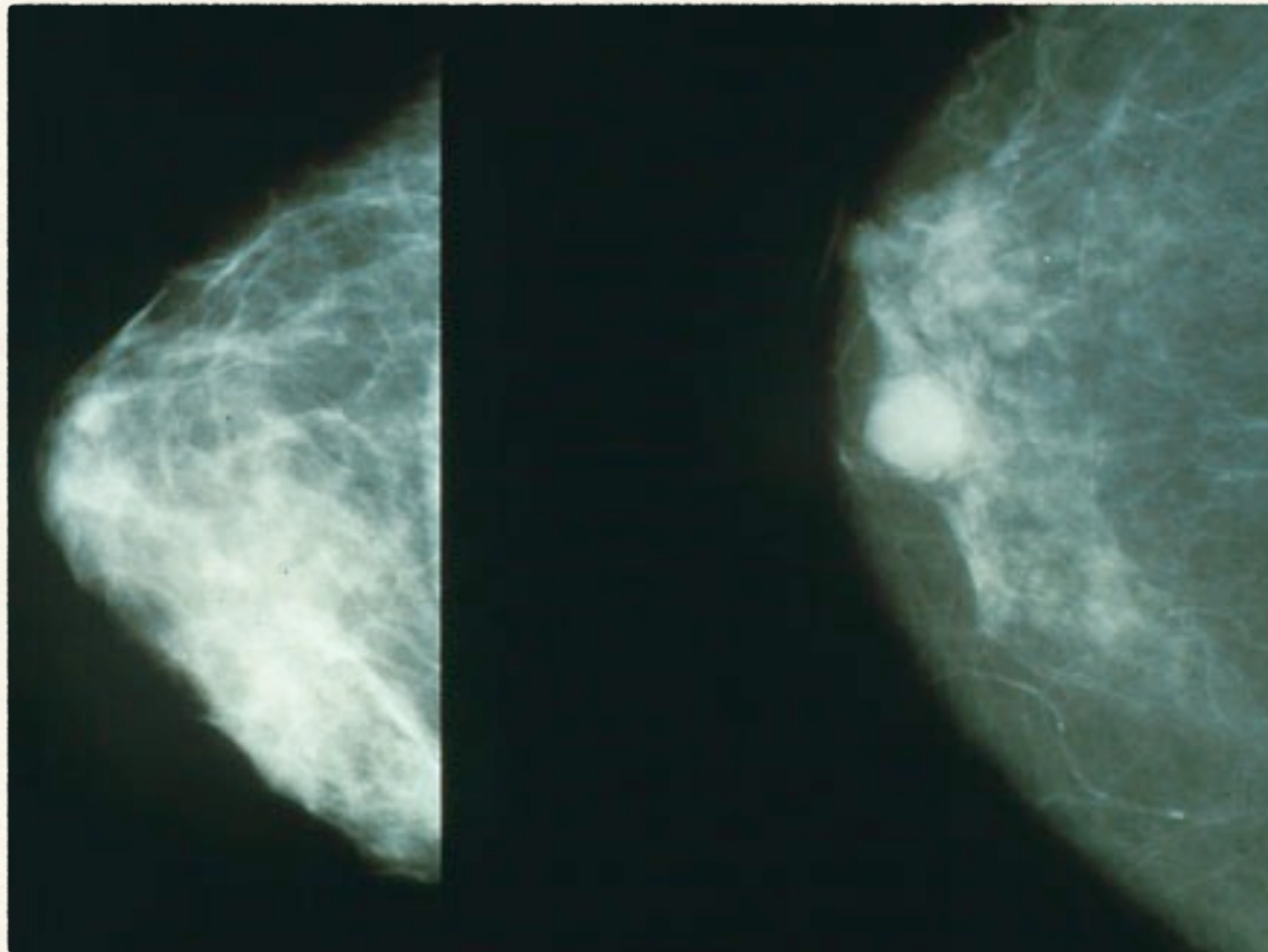


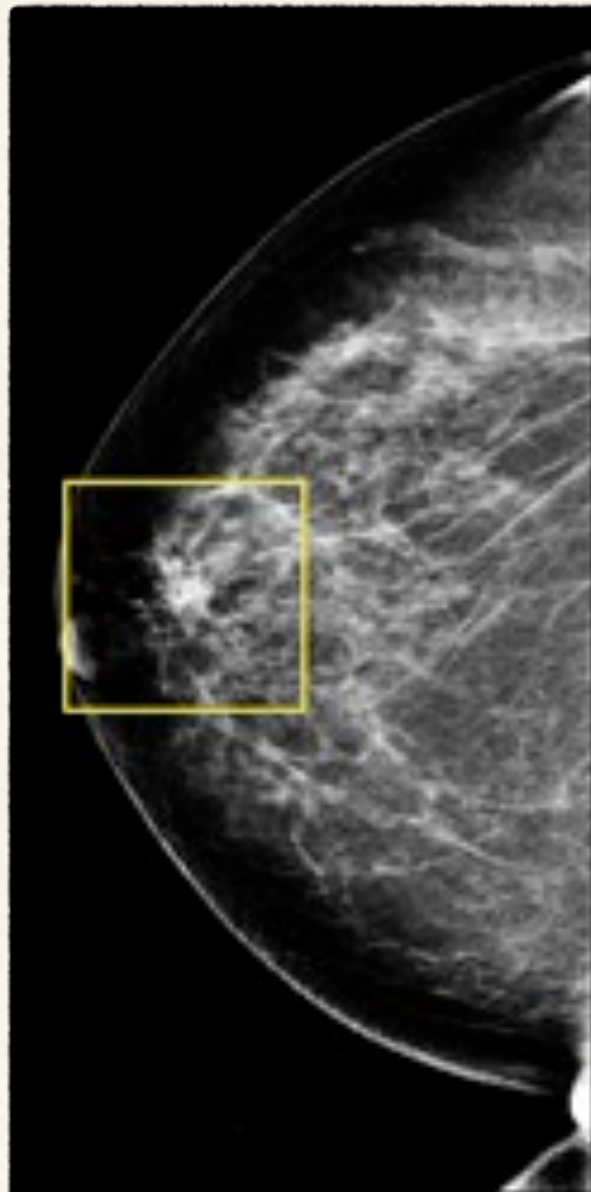


Klinik – 2

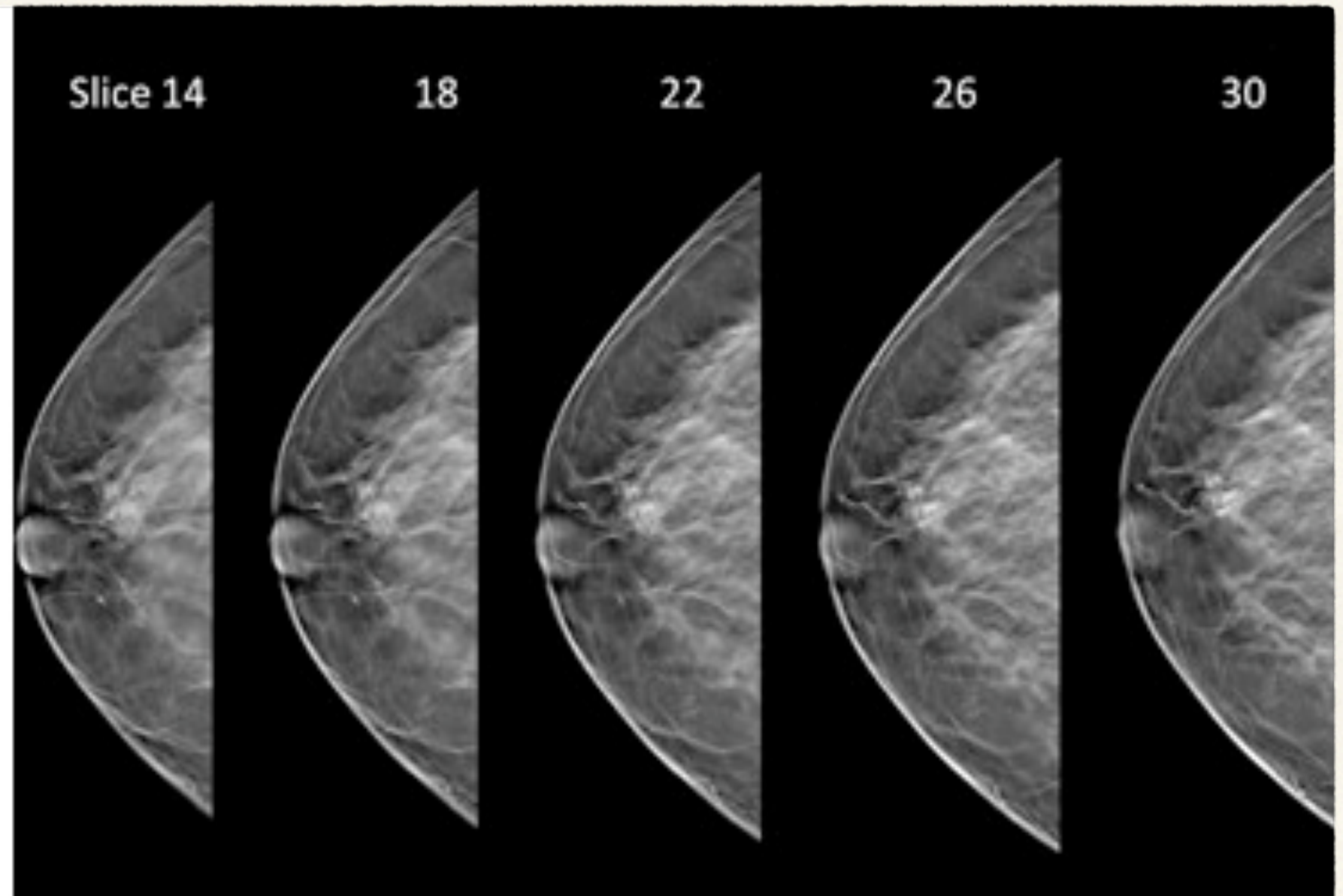
- * Mamografi
- * Ultrasonografi
- * Manyetik rezonans görüntüleme
- * Kendi kendine muayene
- * Klinik muayene



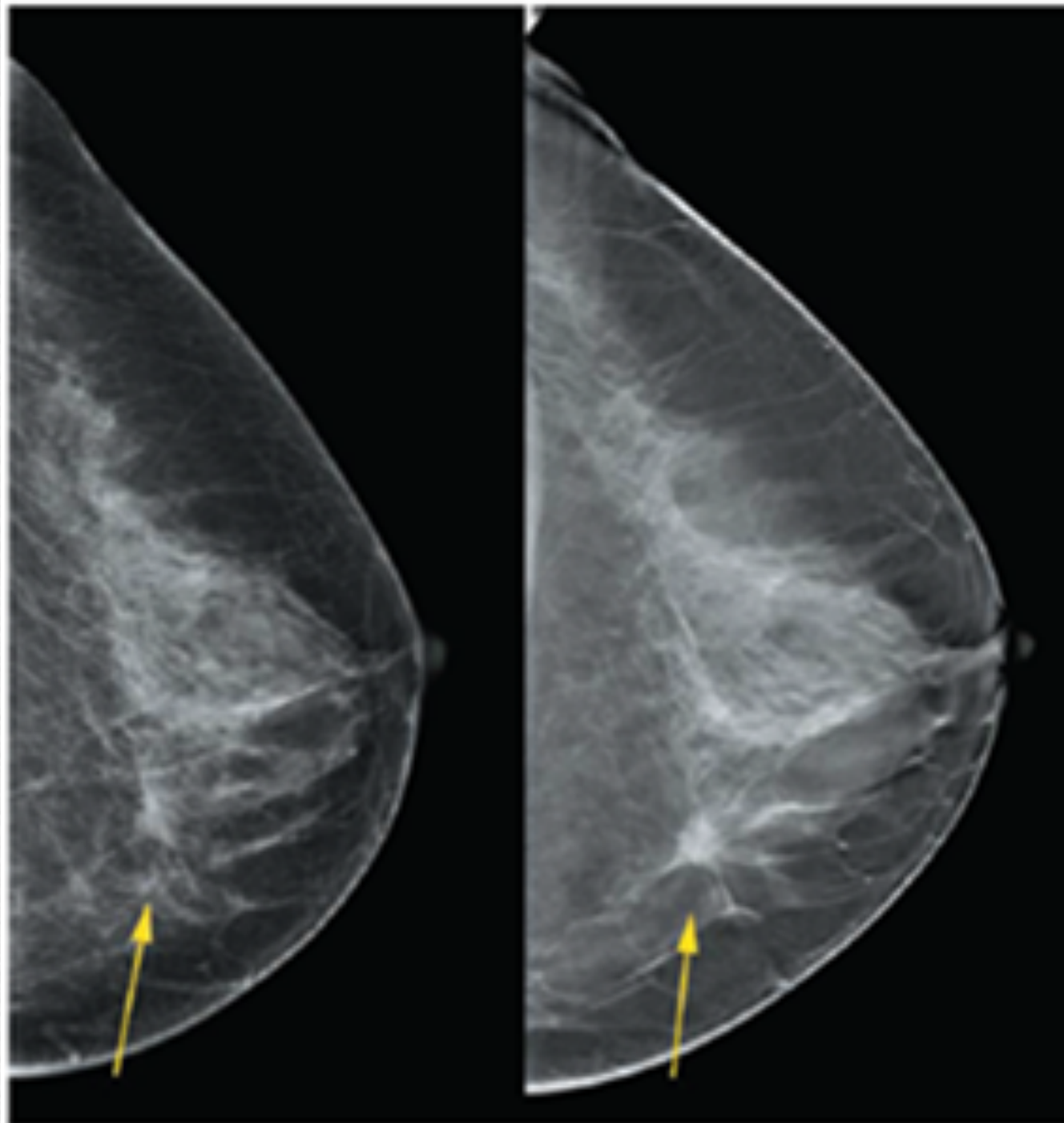




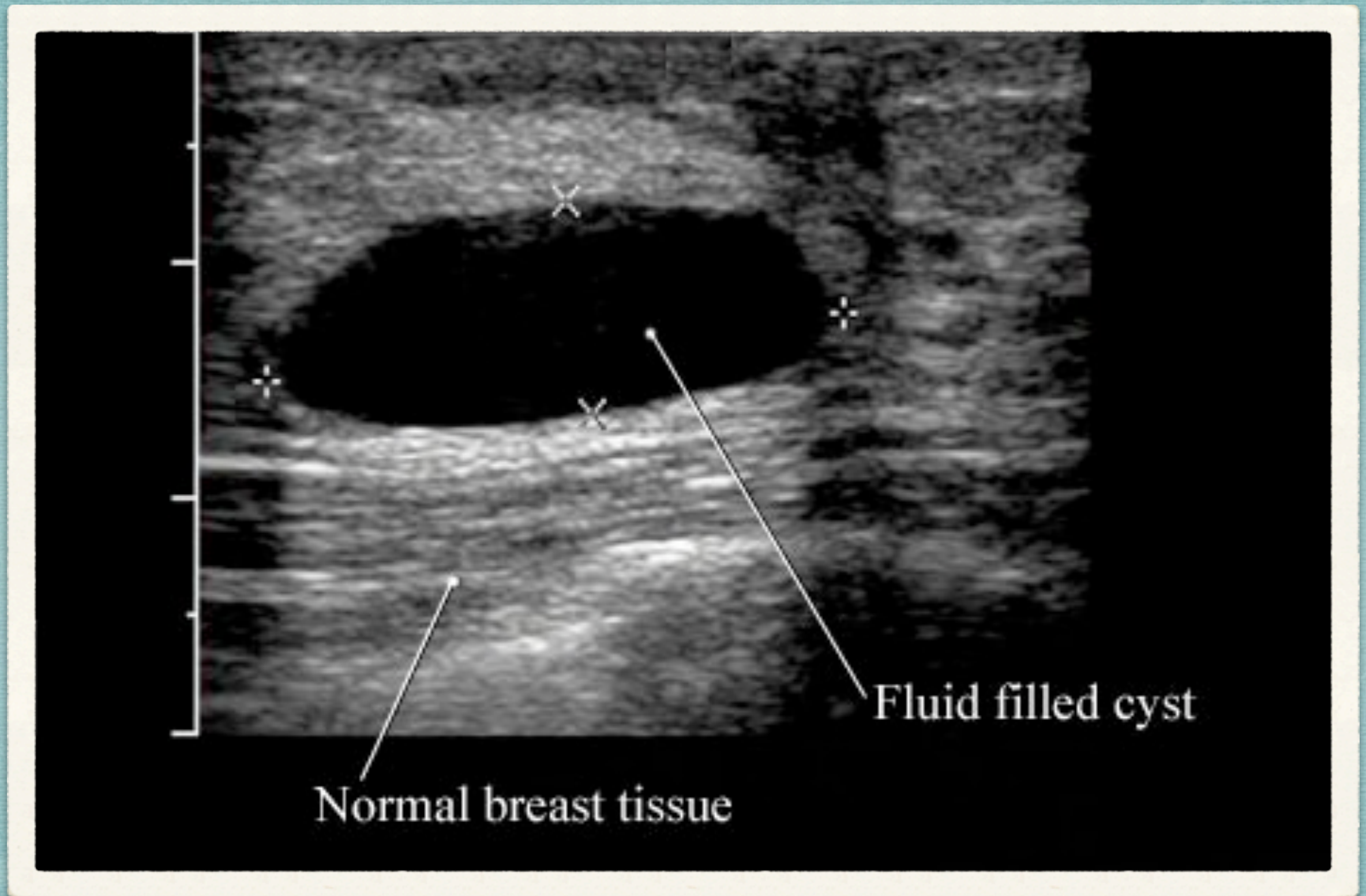
Standard 2-D
Mammogram image

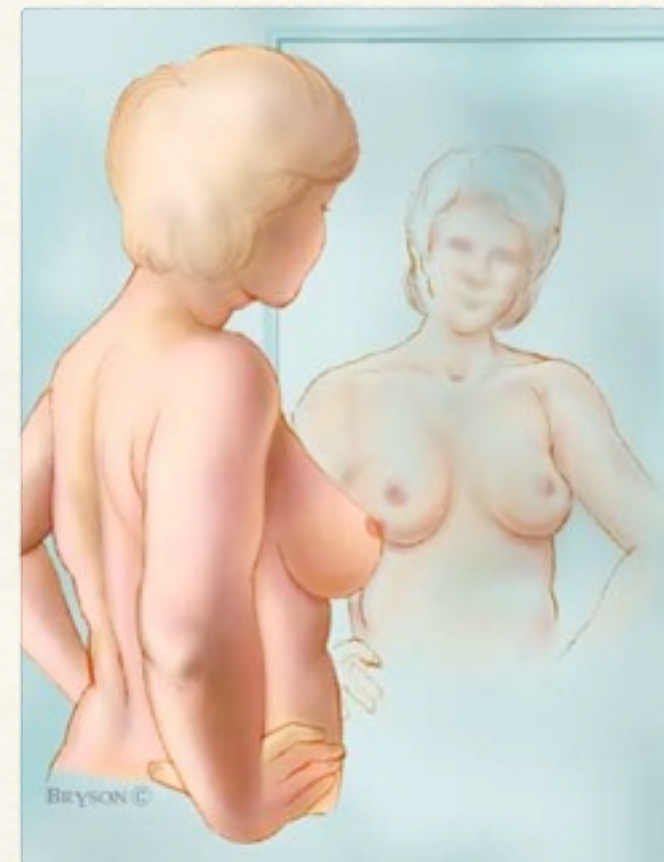
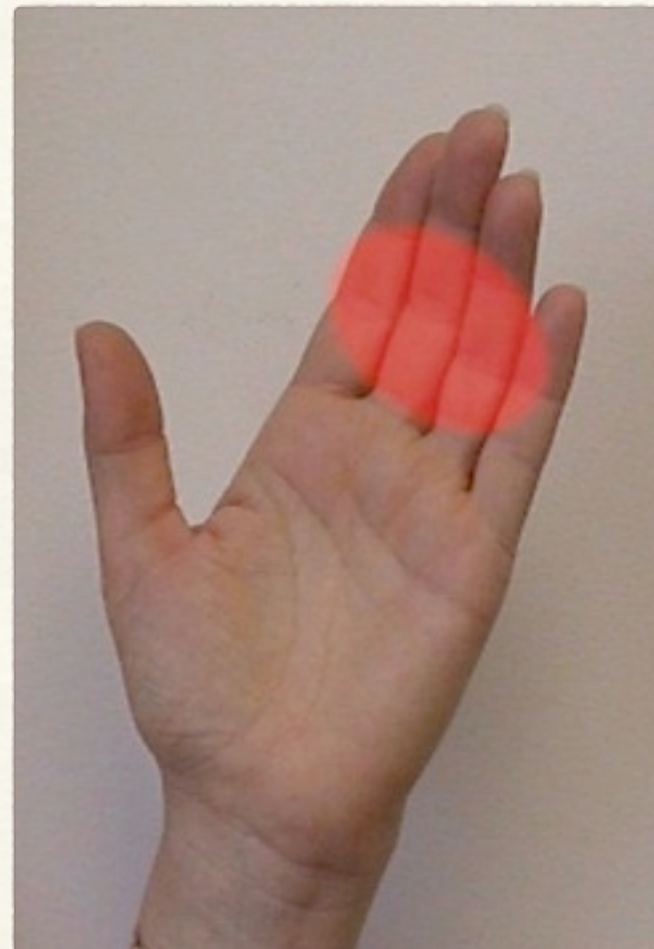
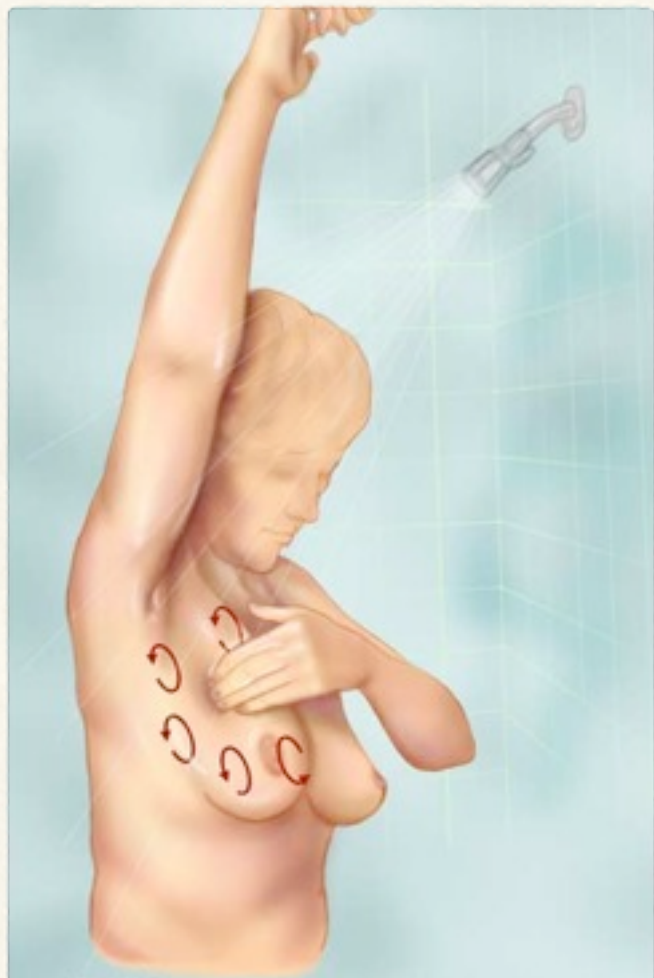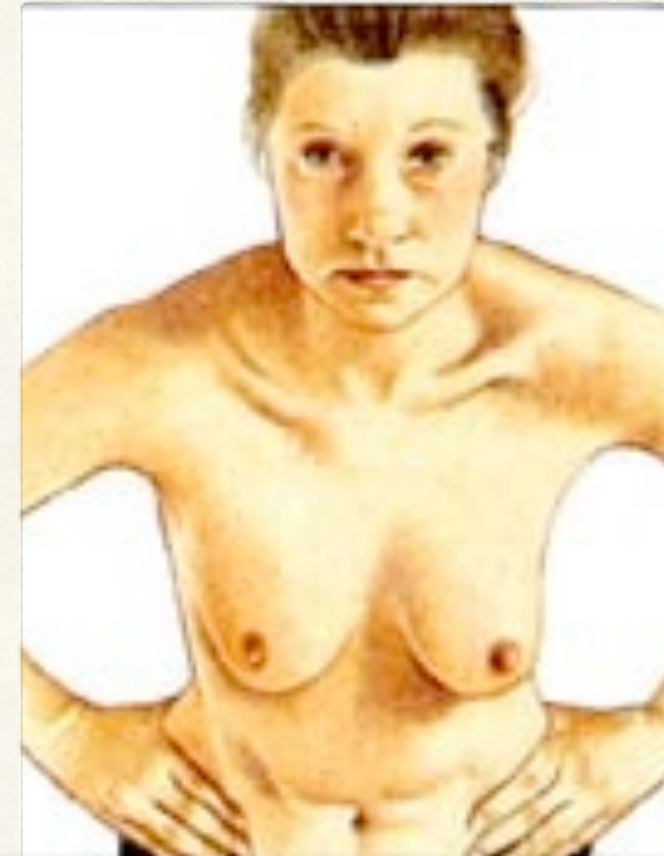

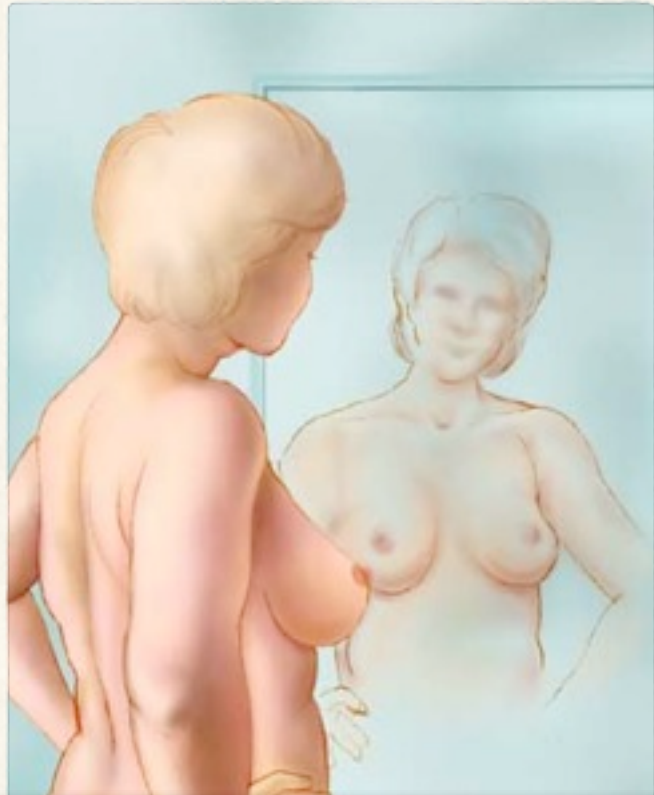
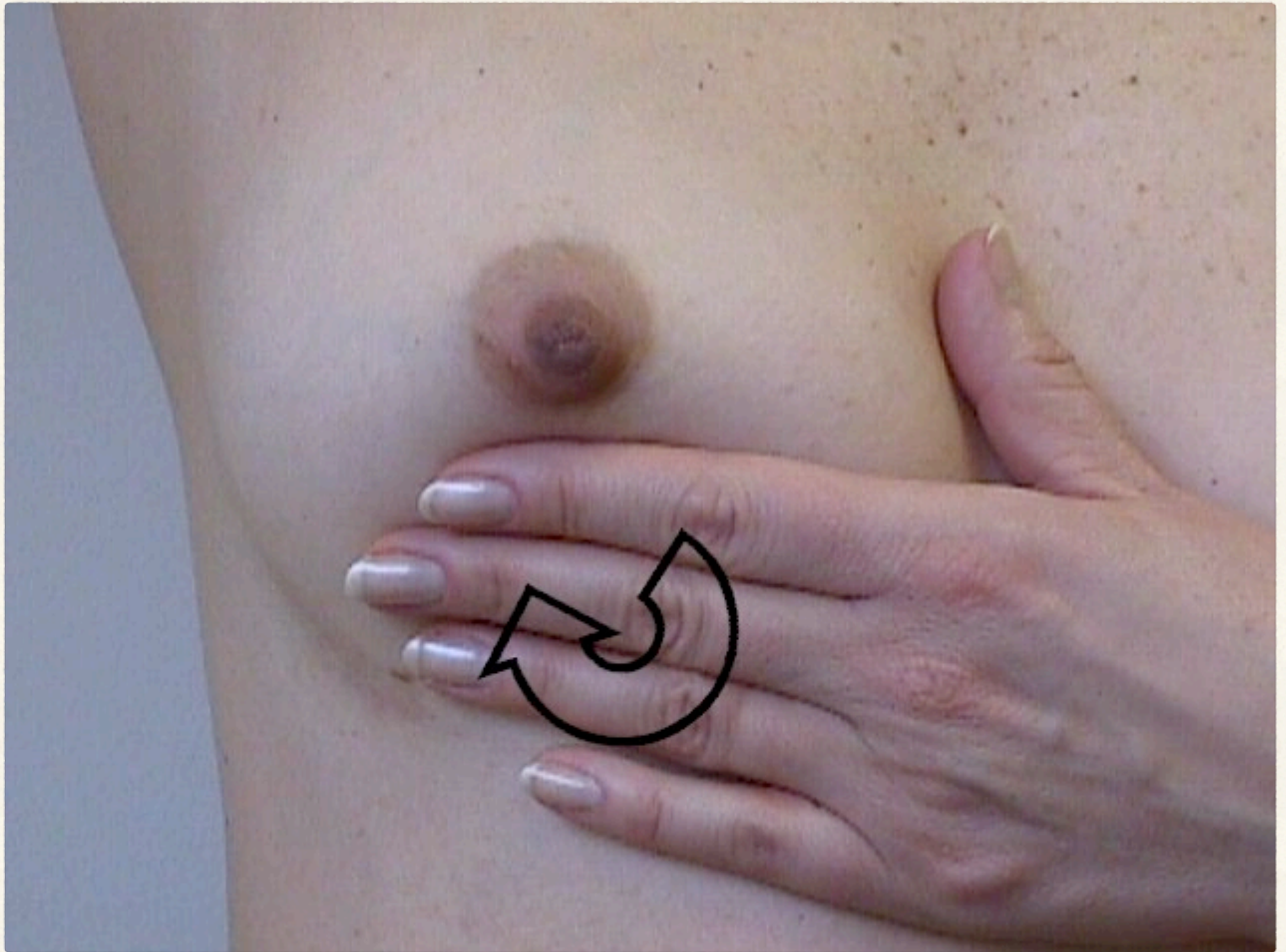
3-D Mammography slices

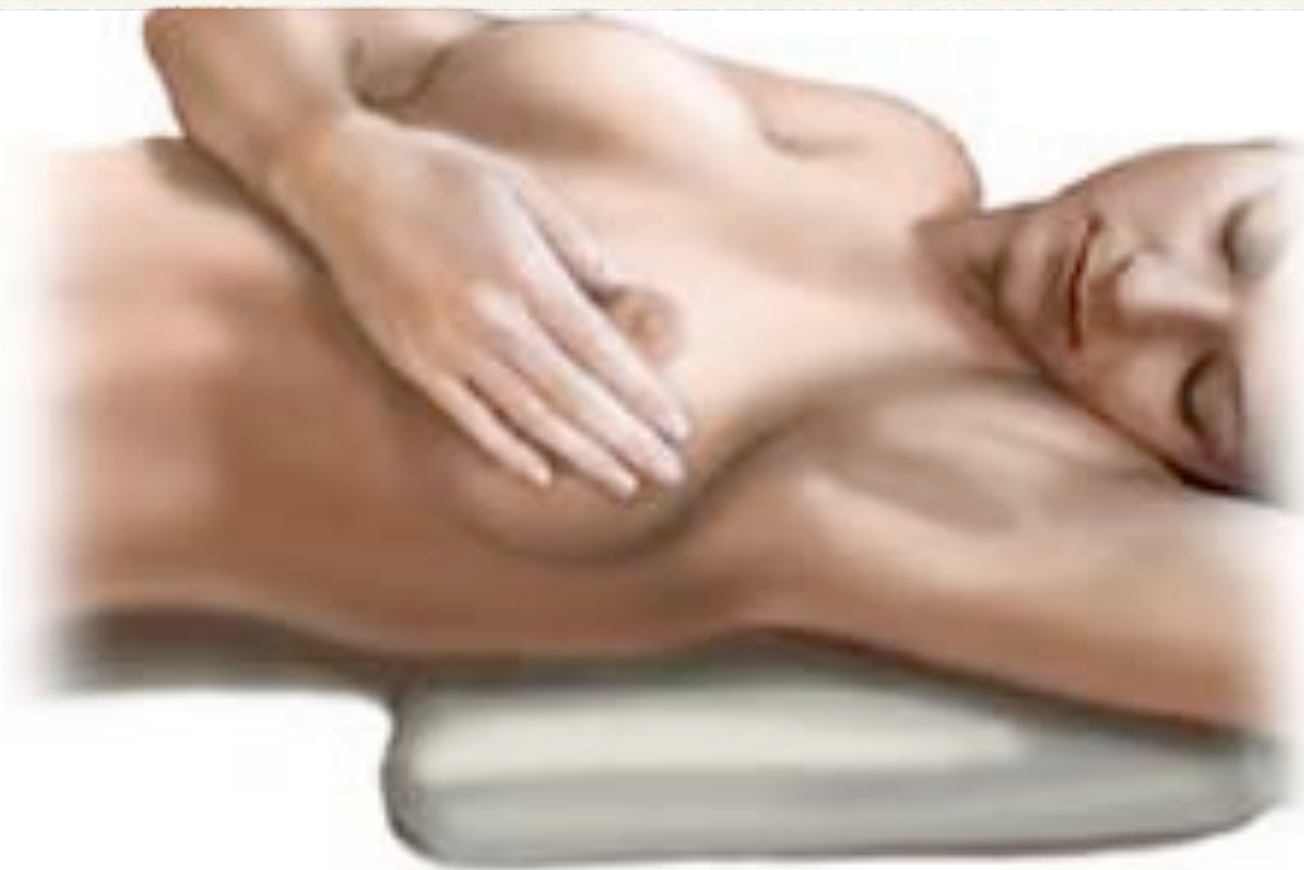

Shown with an arrow, a spiculated cancer with microcalcifications is better appreciated in the tomosynthesis slice (right image) than on the digital mammography image (left image)



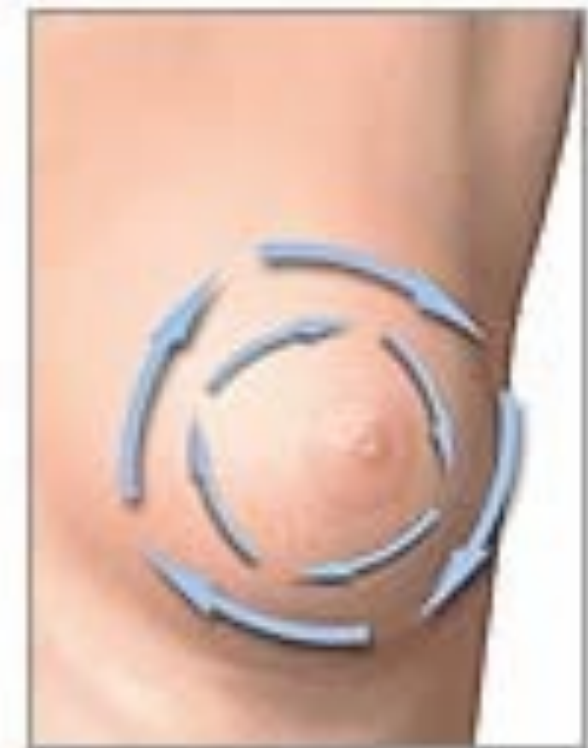
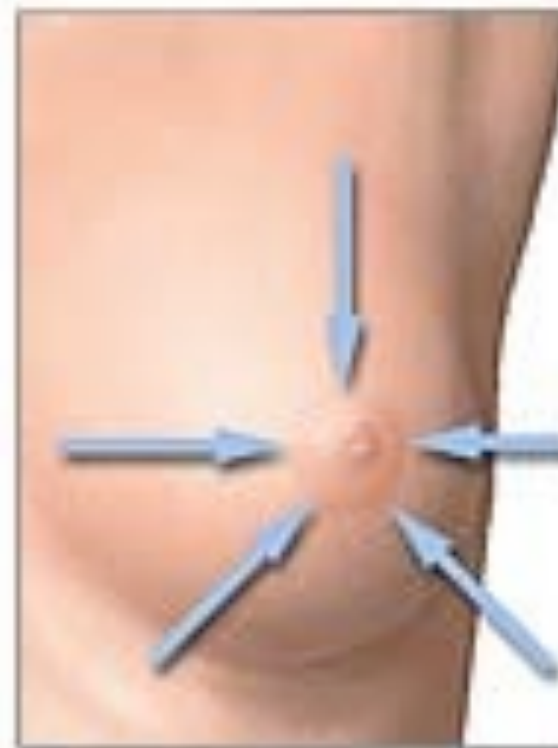
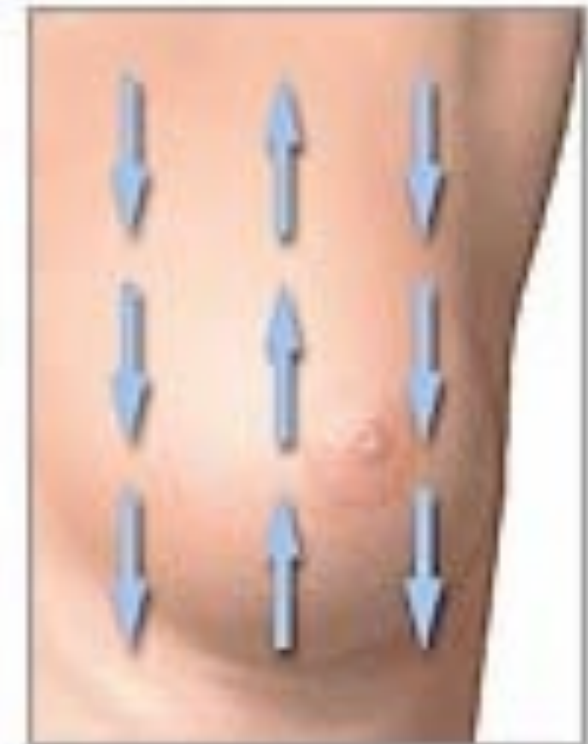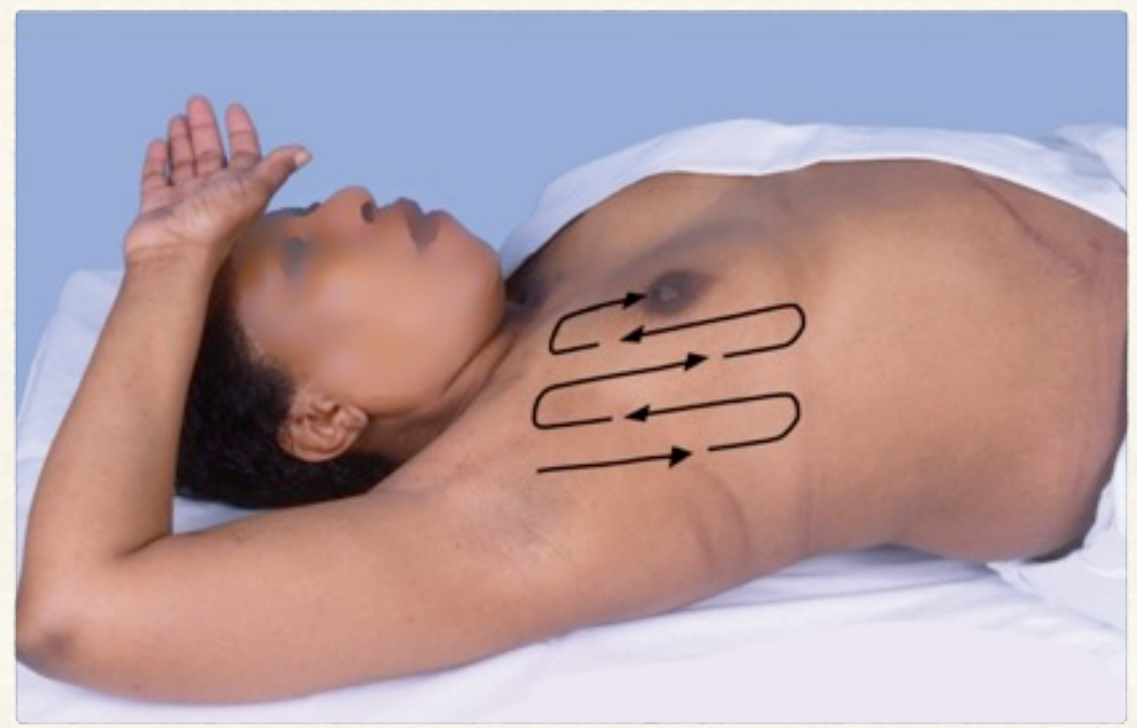



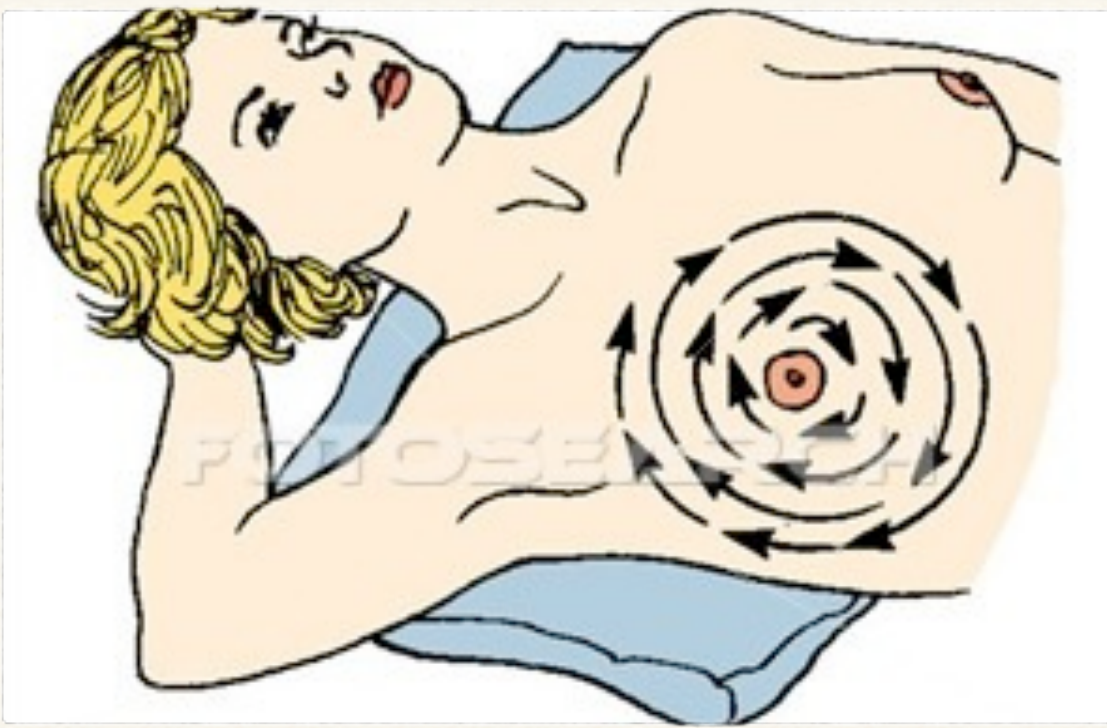
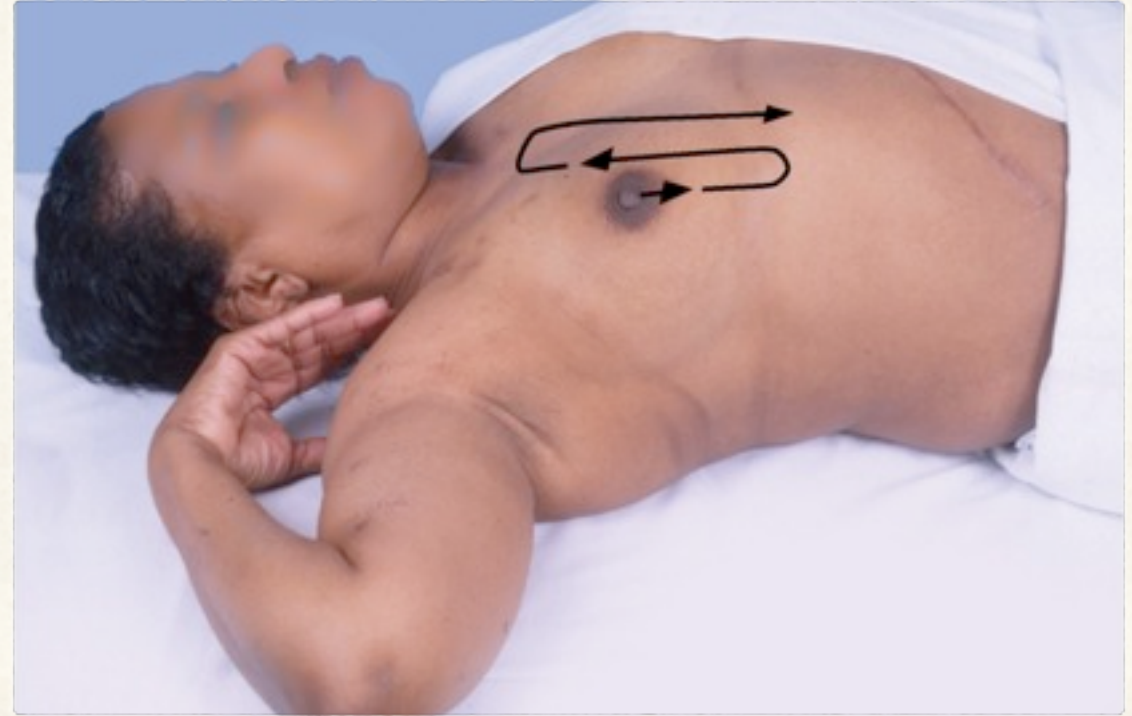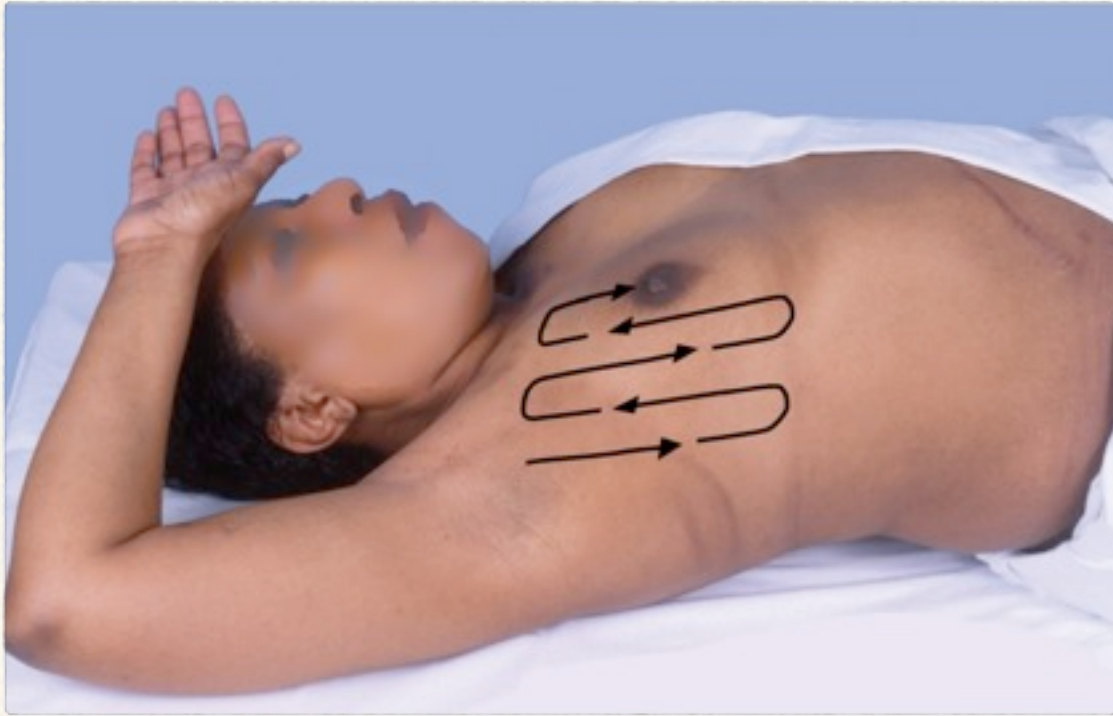Breast self-exam:
Manual inspection
(reclining)

With fingertips close
together, gently probe
each breast in one of
these three patterns







stunali@etu.edu.tr

selcuk@hawaii.edu

<http://twitter.com/tunalis>

<http://www.tunalis.org>